TL-HEX Foot correction guide

ORTHOFIX

NORMAL FOOT ANATOMY

Normal Kite Angle

Normal foot anatomy

NORMAL FOOT ANATOMY

0° normal plantar angle

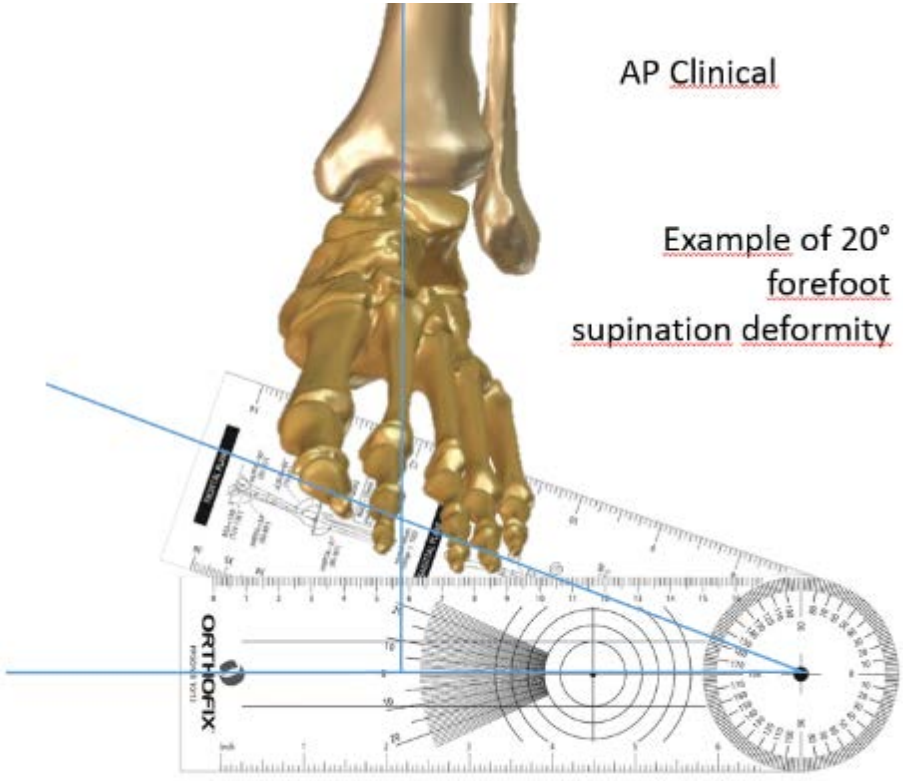

Example of 25° forefoot supination deformity

ORTHOFIX

NORMAL FOOT ANATOMY

The angle between the talar axis and the horizontal Plane is 24,5°

The angle between the Horizontal Plane and the Forefoot Axis is 22°

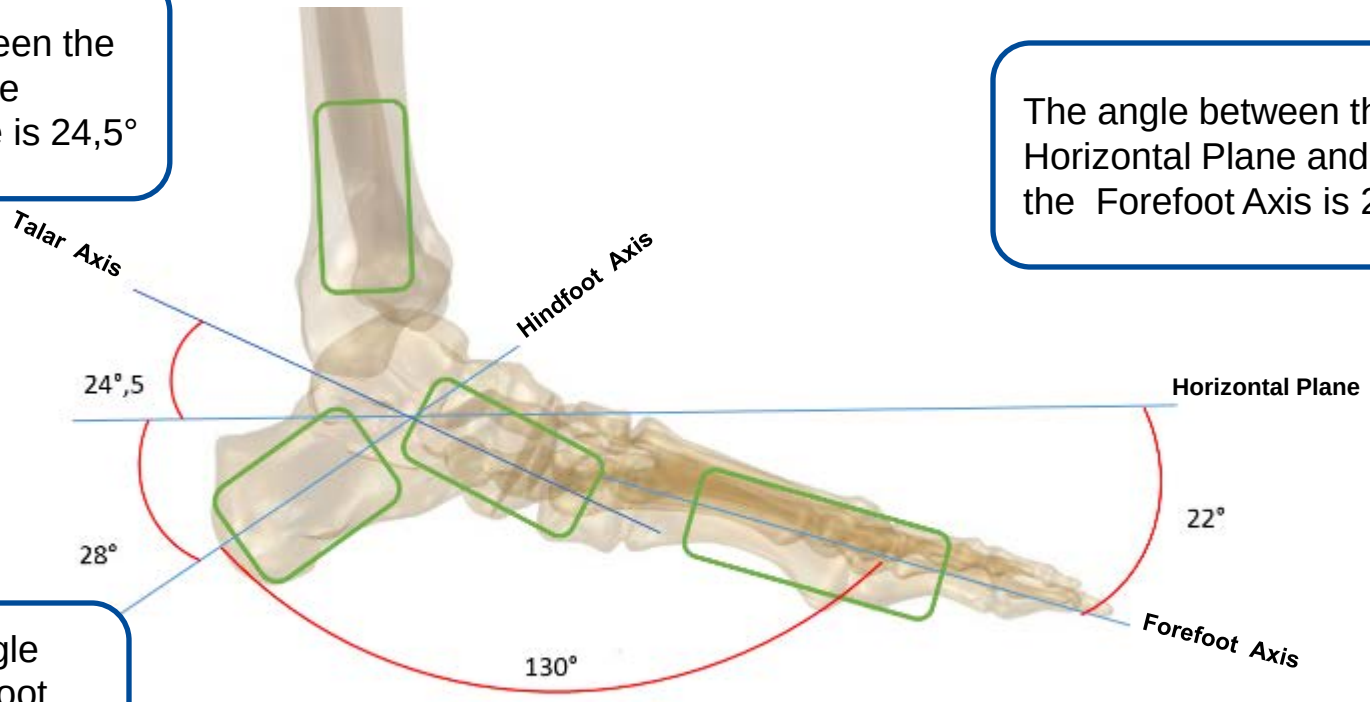

The calcaneus angle between the Hindfoot Axis and the Horizontal Plane is 28°

The angle between the Axis of the Hindfoot and Forefoot is 130°

ORTHOFIX

NORMAL FOOT ANATOMY

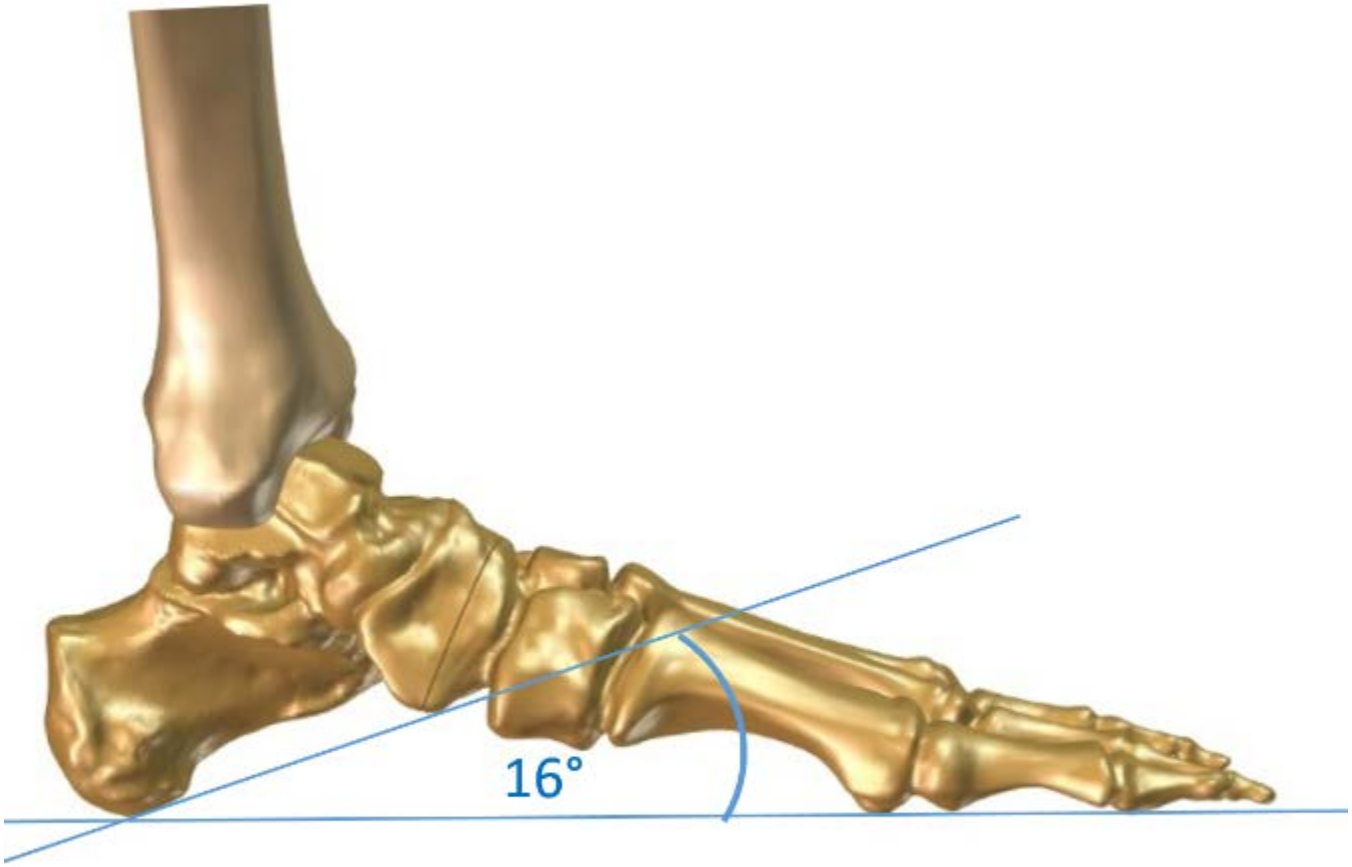

Normal Calcaneal Pitch

GENERAL RULES

1. **Use dorsal view as preferred orientation** (plantar is also possible)

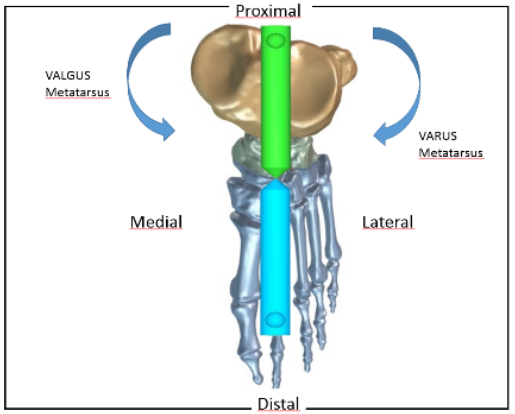

2. Use right (Long bone) for right foot and left (Long bone) for left foot

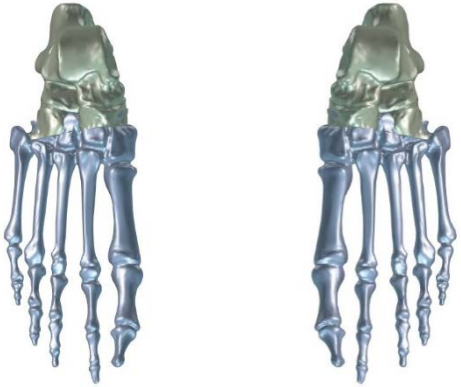

3. The SW rapresentation and the real xray must overlap (see the following slides)

ORTHOFIX

GENERAL RULES

- Think the foot as Long Bone
- Two fragments involved
- Frame = 2 rings + 6 struts/deformity
- Use distal reference

Moving fragment= Proximal

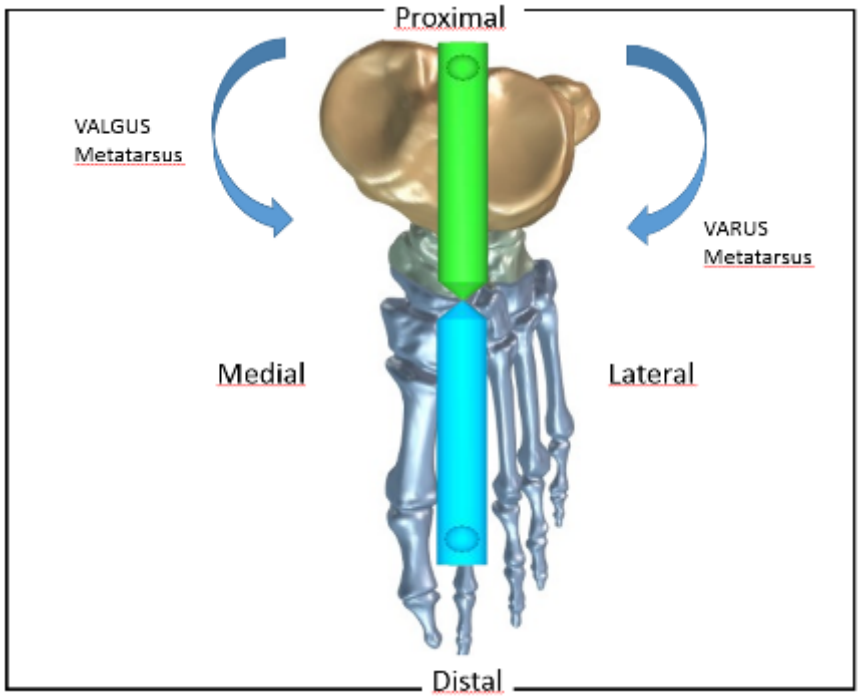

Reference fragment= Distal

ORTHOFIX

LATERAL VIEW (F)

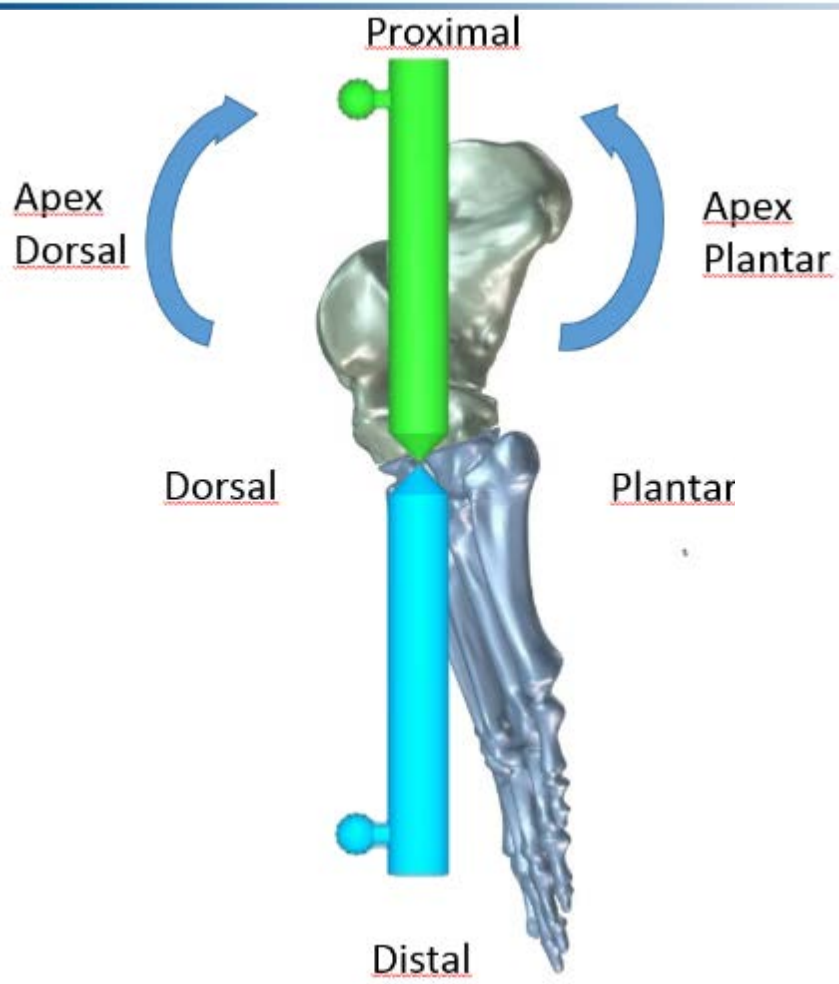

Left and right foot have a symmetric representation

AXIAL VIEW

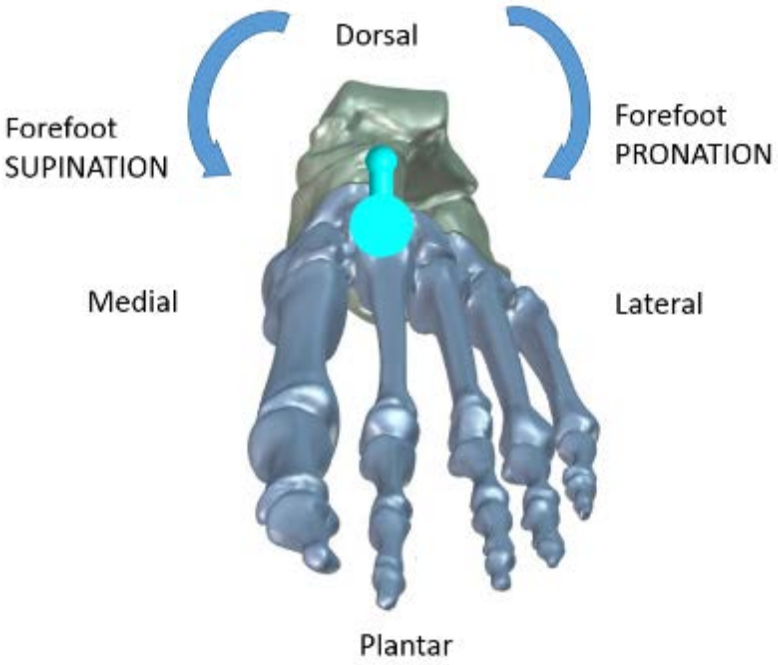

ORTHOFIX

AP View deformity inputs (F)

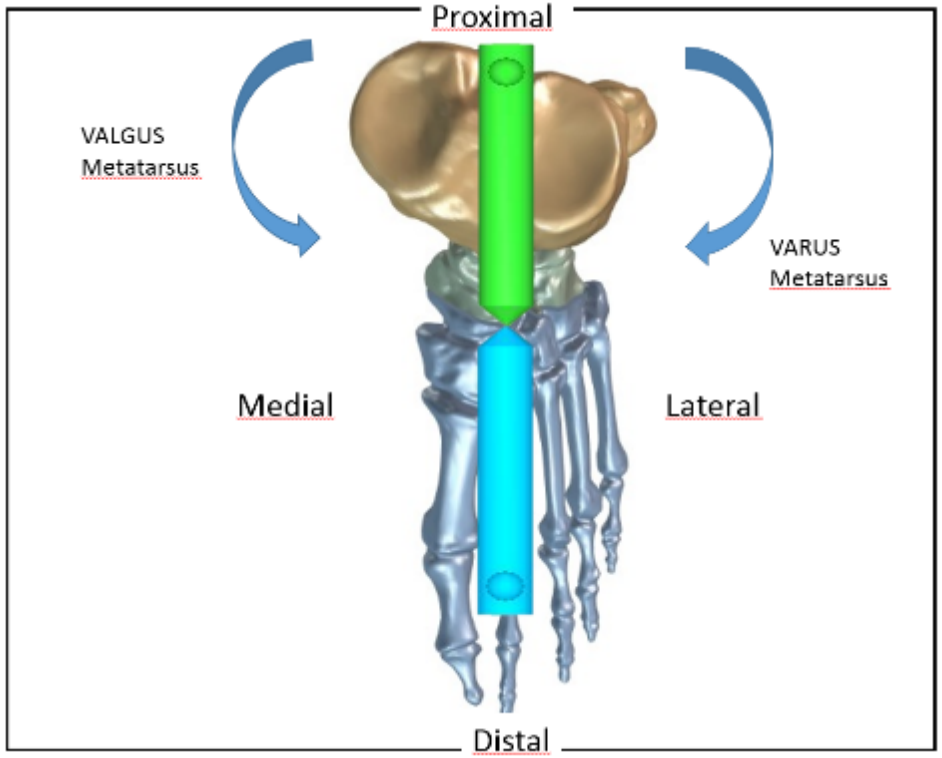

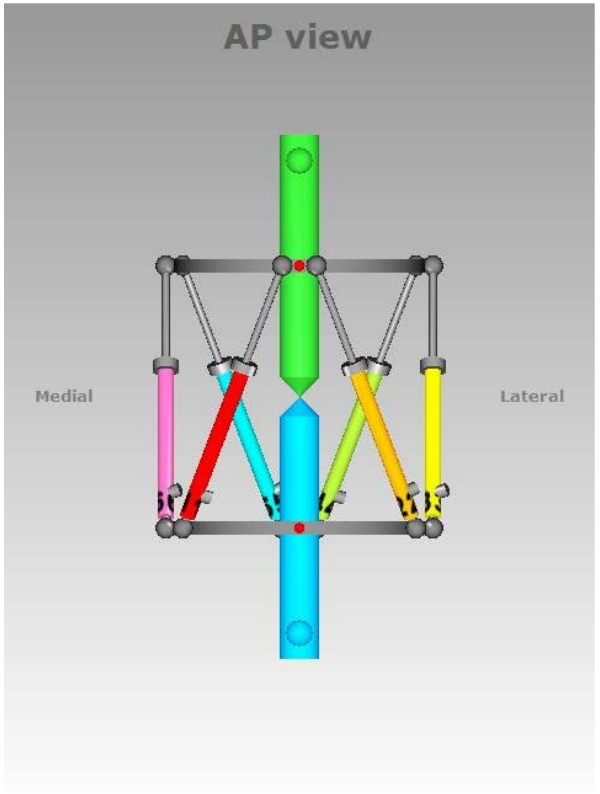

Use Long Bone option

Select one of the two options

(Forefoot)

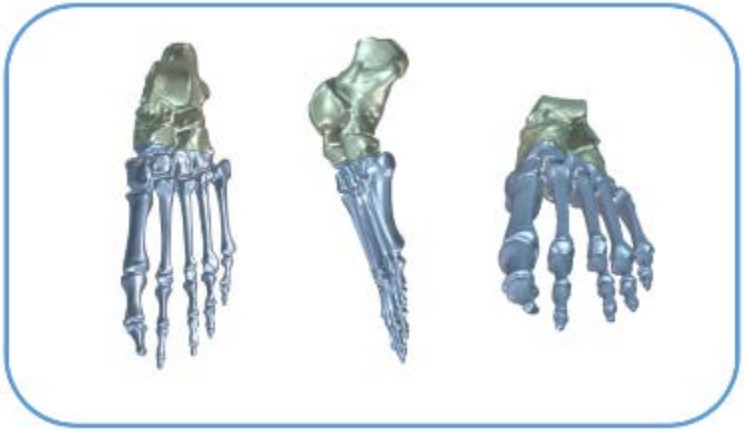

(Hindfoot)

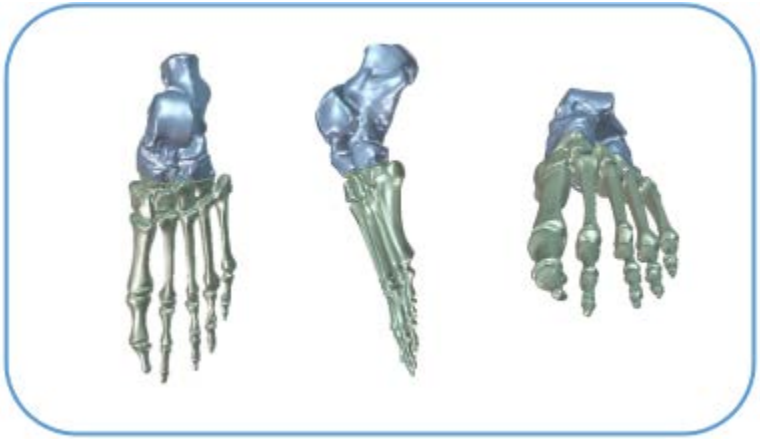

ORTHOFIX

AP VIEW (Forefoot)

Right Foot

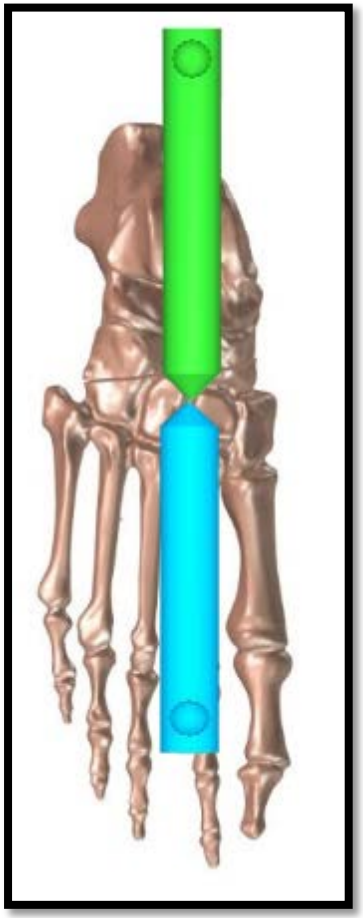

Left Foot

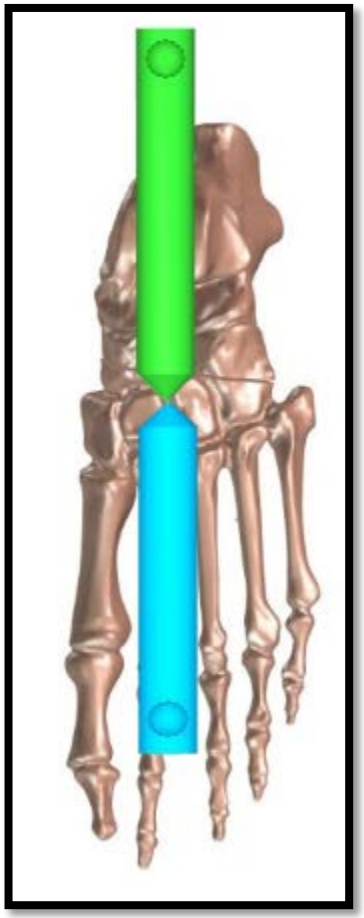

Click on Image

ORTHOFIX

Full Rings

5/8 Rings

Click on Image

ORTHOFIX

RIGHT FOOT Anatomical – Forefoot (Reference segment Distal) with Full Rings

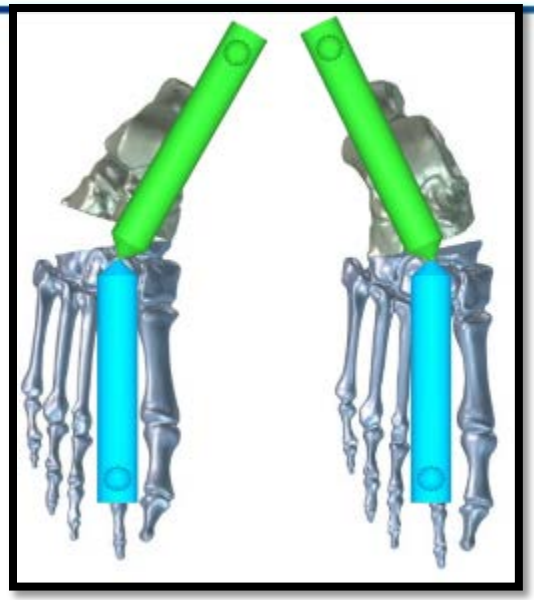

Varus Valgus



Lateral Medial

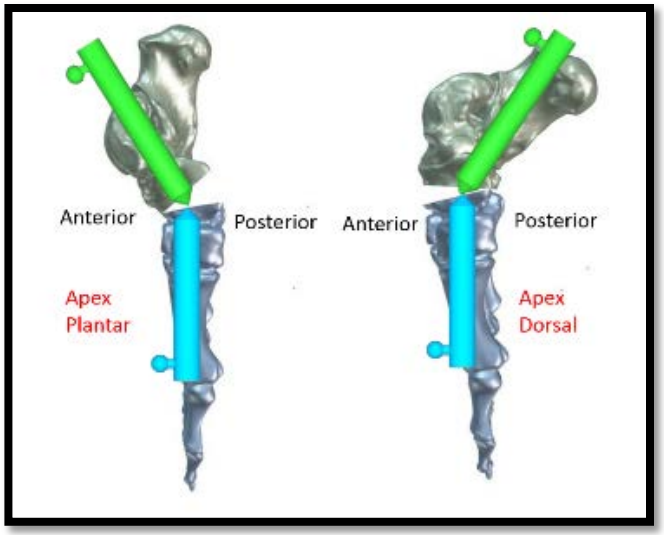

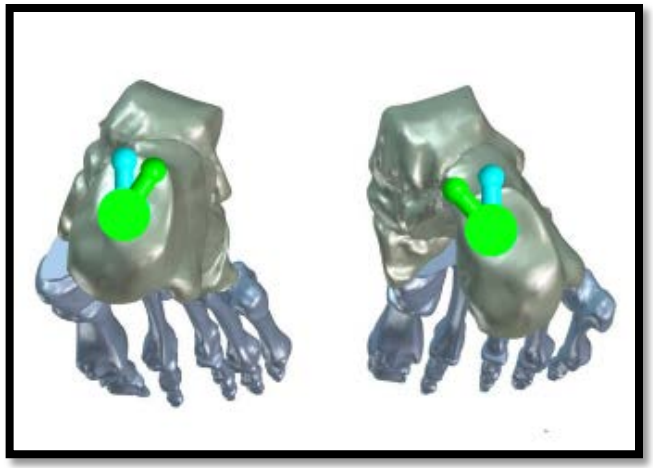

Supination Pronation

Click on Image

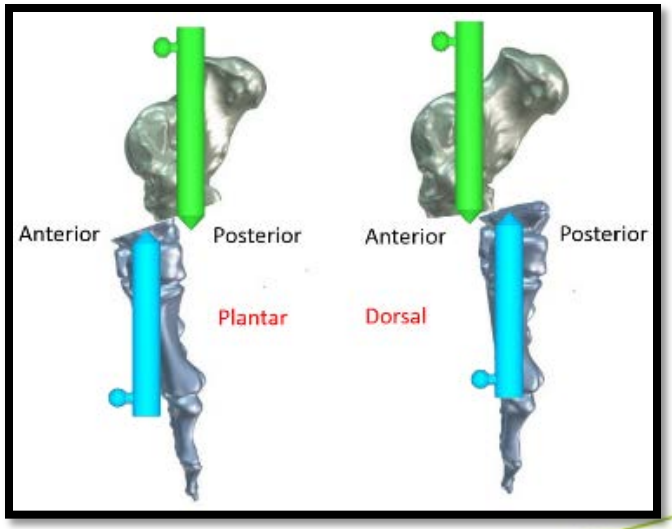

ORTHOFIX

AP View deformity inputs (Full Rings)

RIGHT FOOT

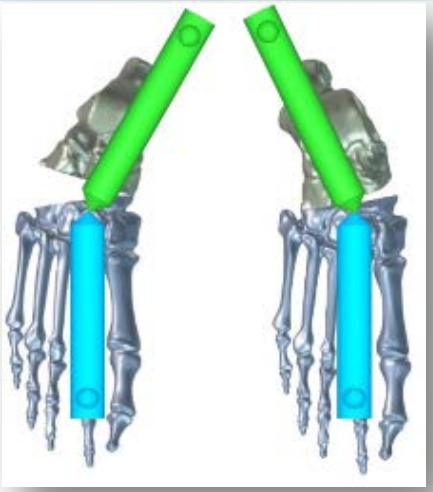

Anatomical Varus

Anatomical Valgus

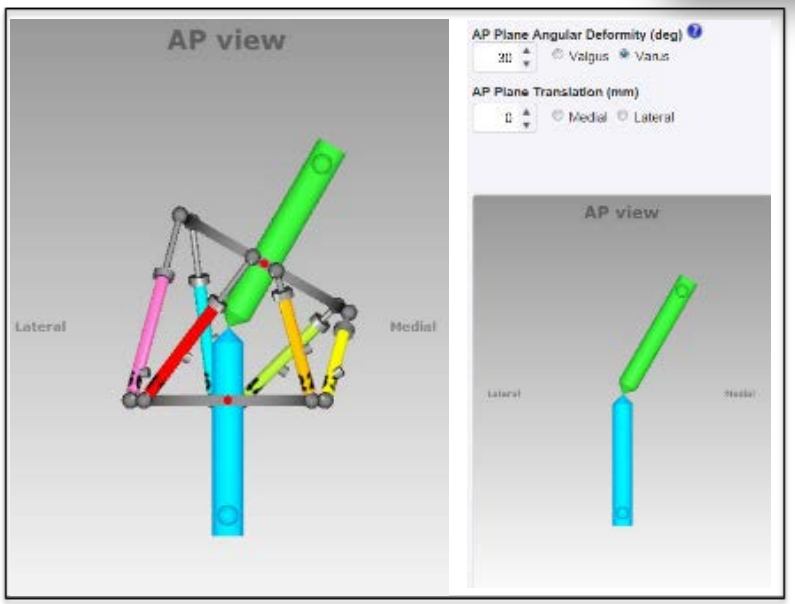

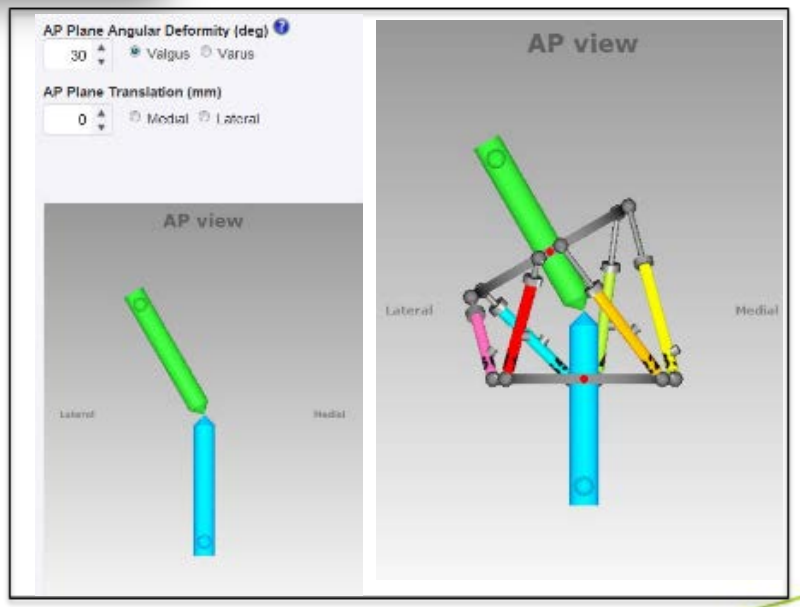

AP View deformity inputs (Full Rings)

RIGHT FOOT



Anatomical
Lateral

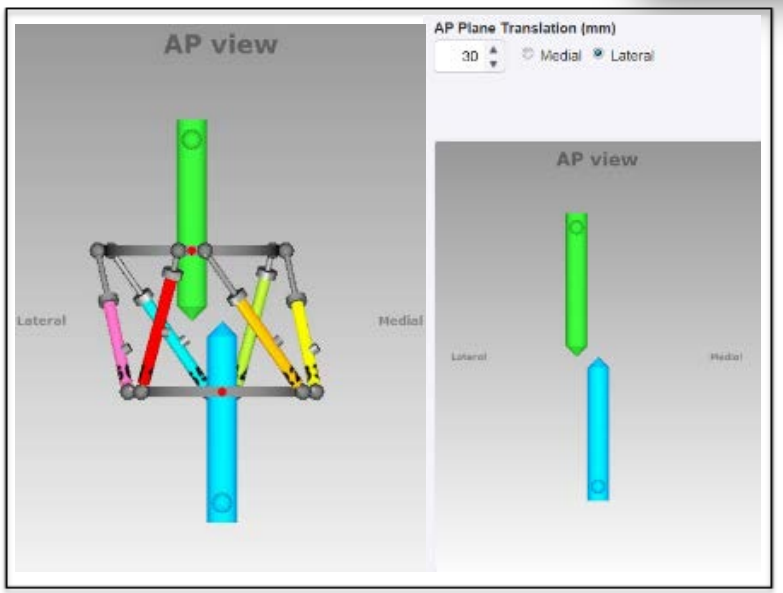

Anatomical
Medial

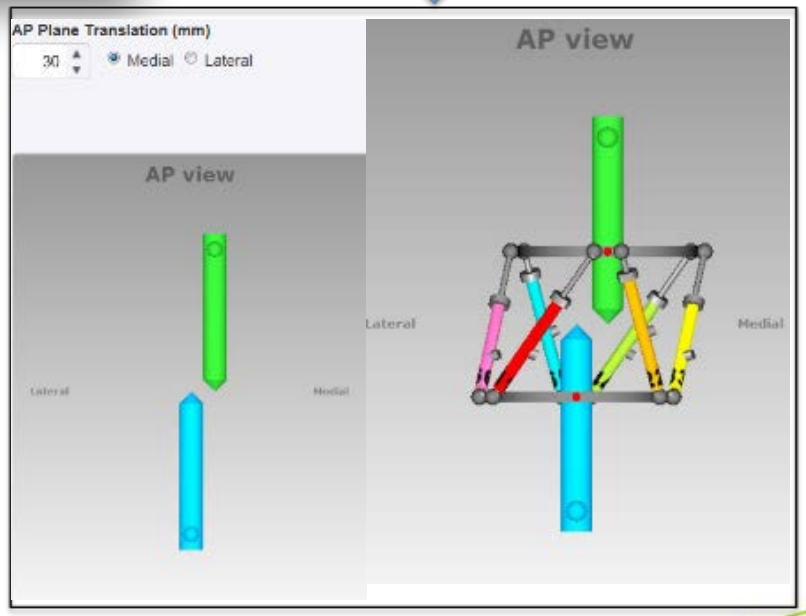

LATERAL VIEW – ANGULATION (Full Rings)

RIGHT FOOT

APEX
POSTERIOR/PLANTAR
(Recurvatum)

Xray Medial

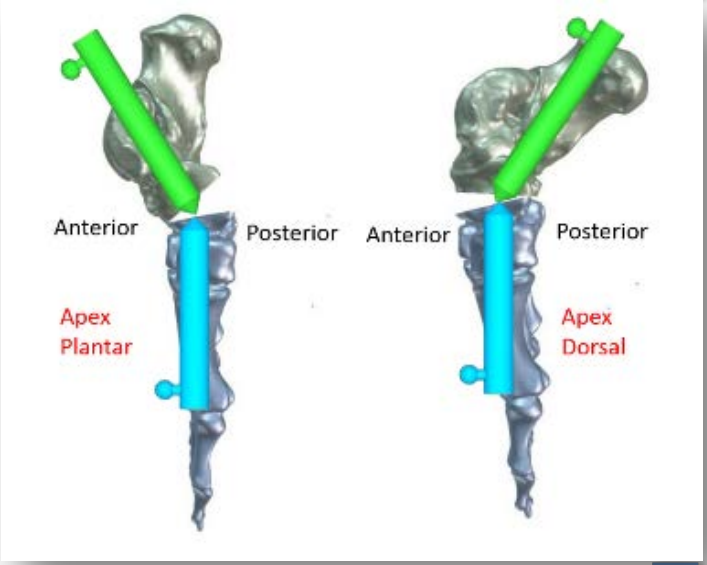

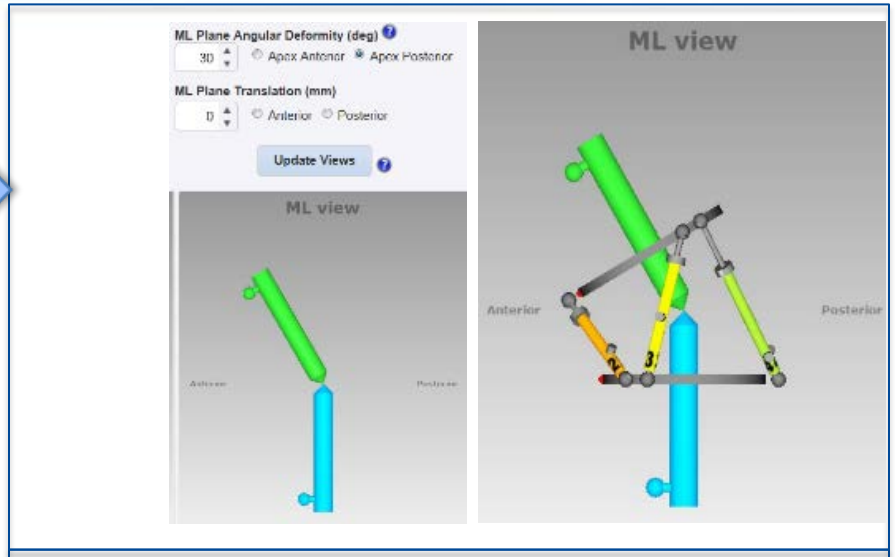

APEX
ANTERIOR/DORSAL
(Procurvatum)

LATERAL VIEW – TRANSLATION (Full Rings)

RIGHT FOOT

TRANSLATION PLANTAR
(posterior translation)

Xray Medial

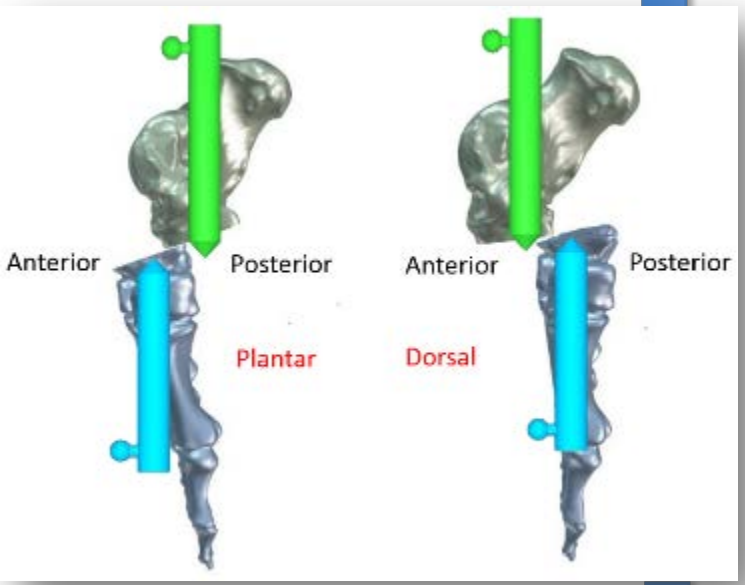

TRANSLATION DORSAL
(anterior translation)

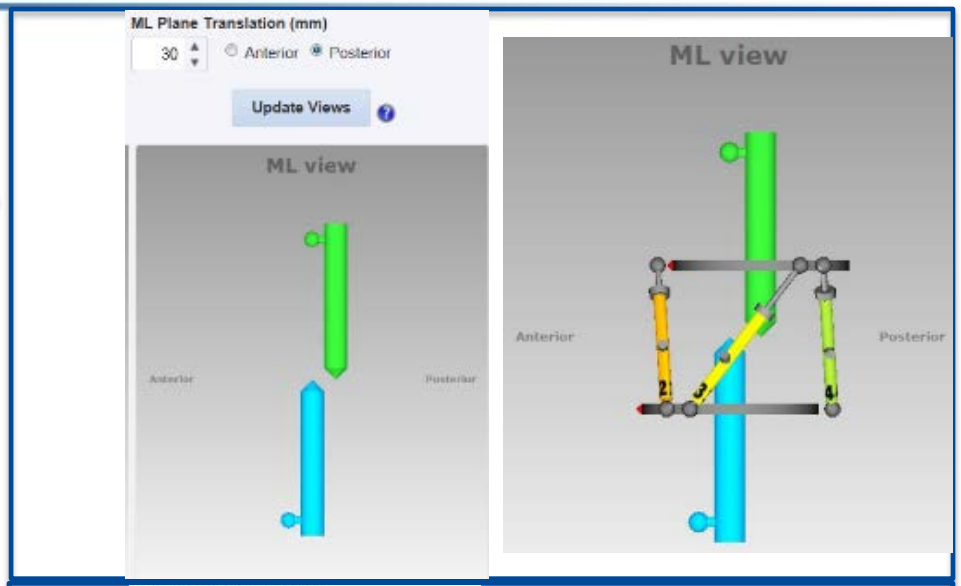

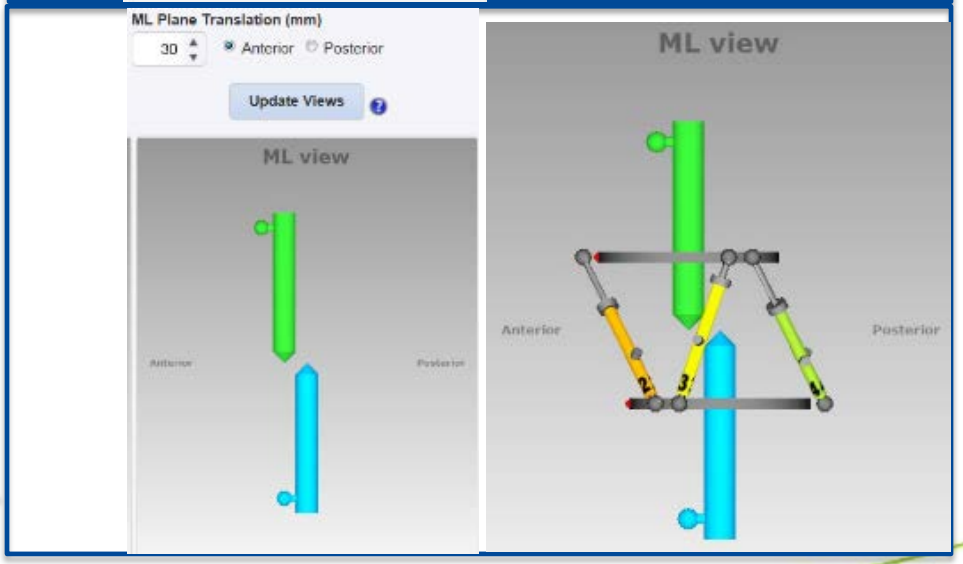

AXIAL VIEW (Full Rings)

RIGHT FOOT

Rotation (deg) 45 External Internal

Axial Translation (mm) 0 Short Long

Bone Length (mm) 0 Short Long

Forefoot Pronation

Forefoot Supination



SW Axial View is from Prox. Segment

Rotation (deg) 45 External Internal

Axial Translation (mm) 0 Short Long

Bone Length (mm) 0 Short Long



ORTHOFIX

RIGHT FOOT Anatomical – Forefoot (Reference segment Distal) with 5/8 Rings

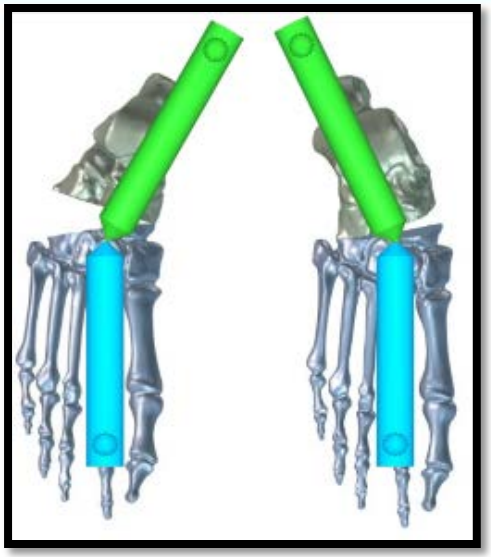

Varus Valgus



Lateral Medial

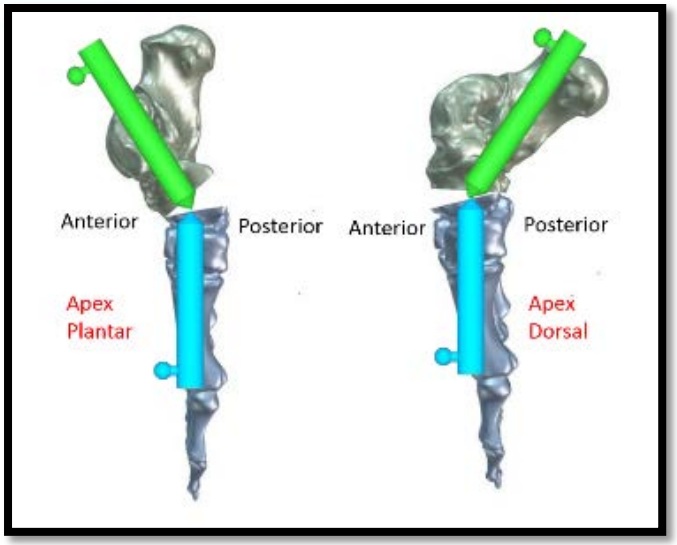

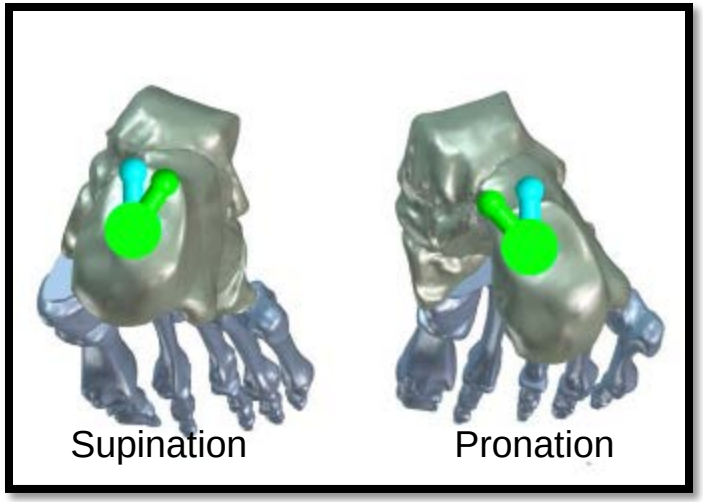

Supination Pronation

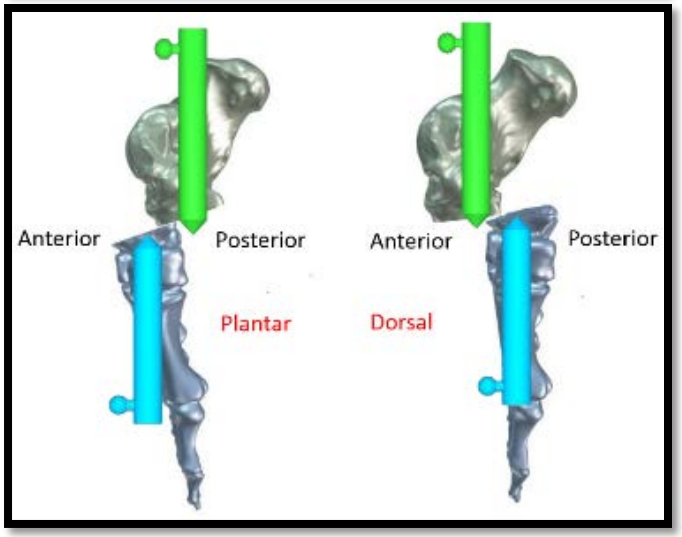

Click on Image

ORTHOFIX

AP View deformity inputs (5/8 Rings)

RIGHT FOOT

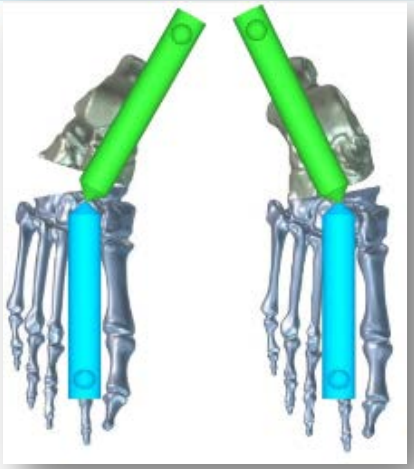

Anatomical Varus

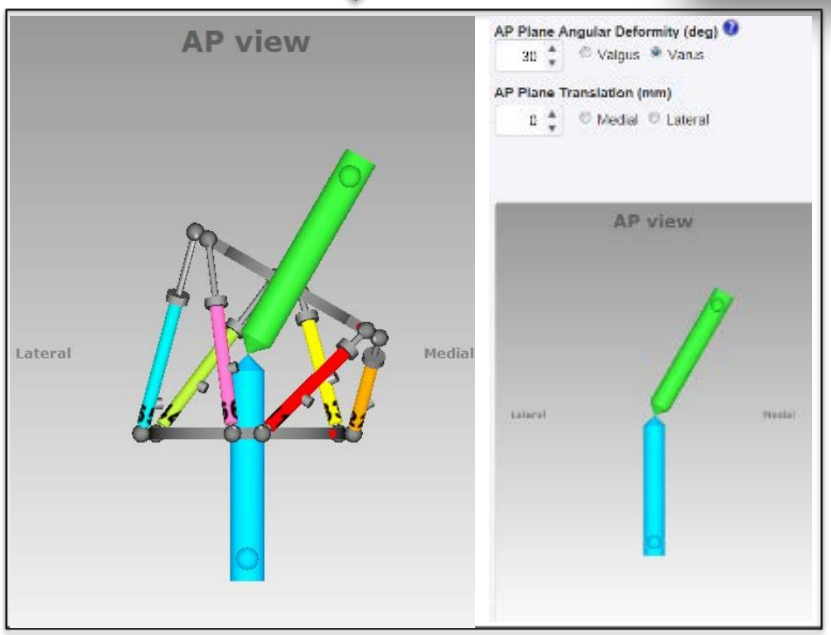

Anatomical Valgus

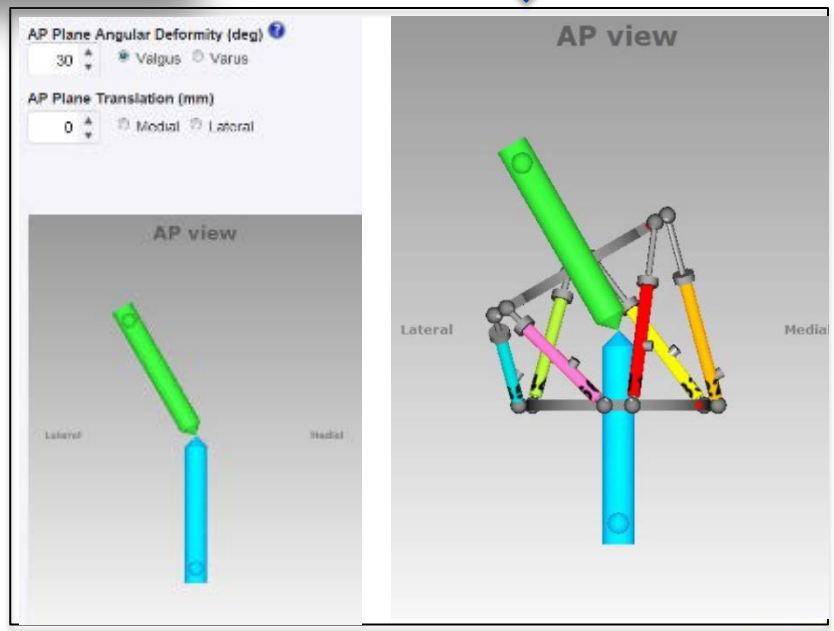

AP View deformity inputs (5/8 Rings)

RIGHT FOOT



Anatomical
Lateral

Anatomical
Medial

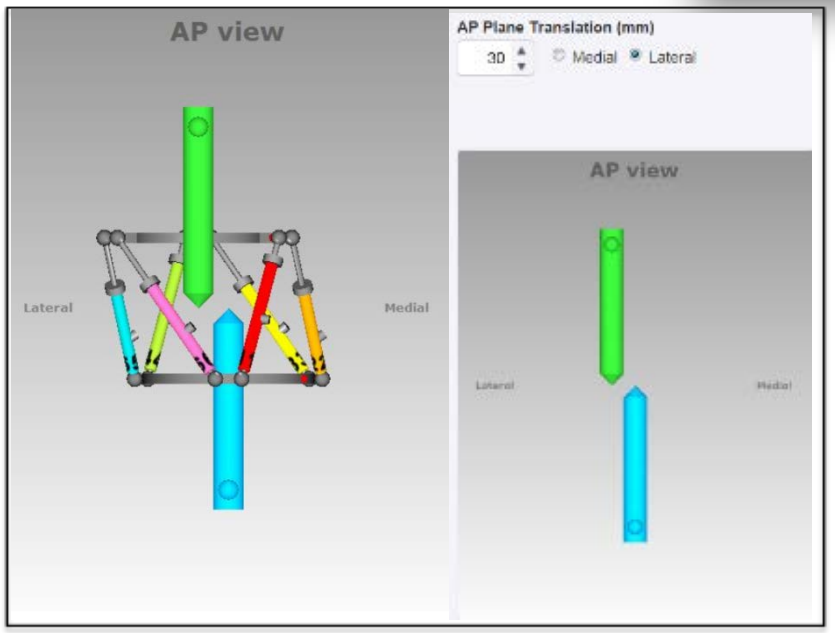

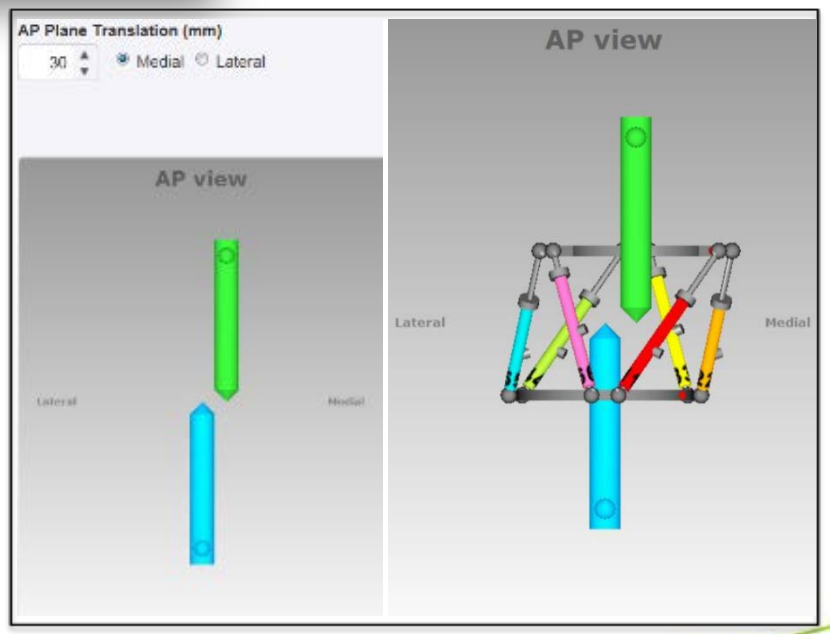

LATERAL VIEW – ANGULATION (5/8 Rings)

RIGHT FOOT

APEX
POSTERIOR/PLANTAR
(Recurvatum)

Xray Medial

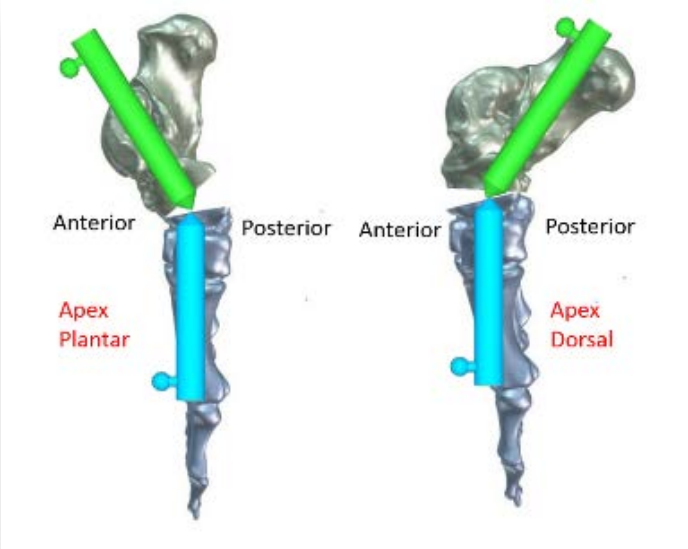

APEX
ANTERIOR/DORSAL
(Procurvatum)

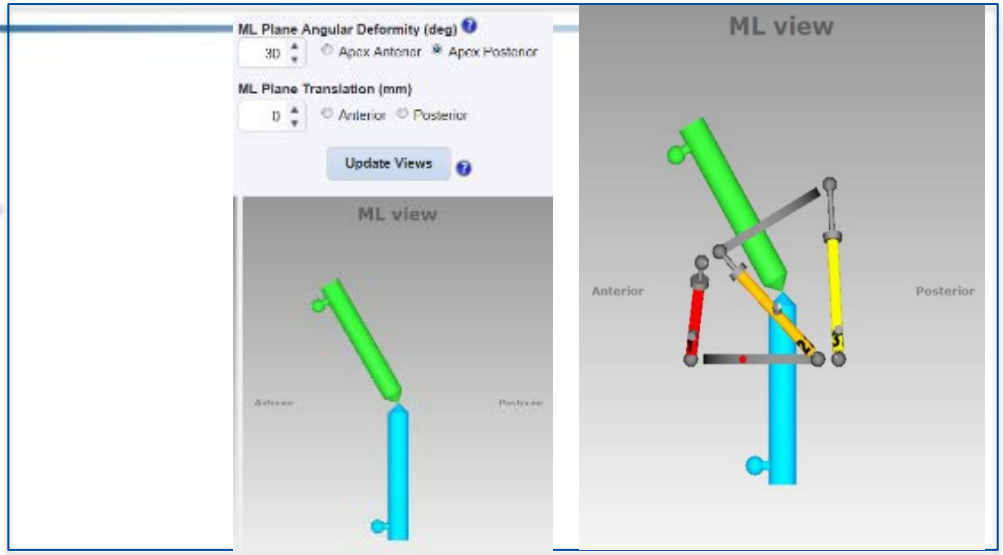

LATERAL VIEW – TRANSLATION (5/8 Rings)

RIGHT FOOT

TRANSLATION PLANTAR
(posterior translation)

Xray Medial

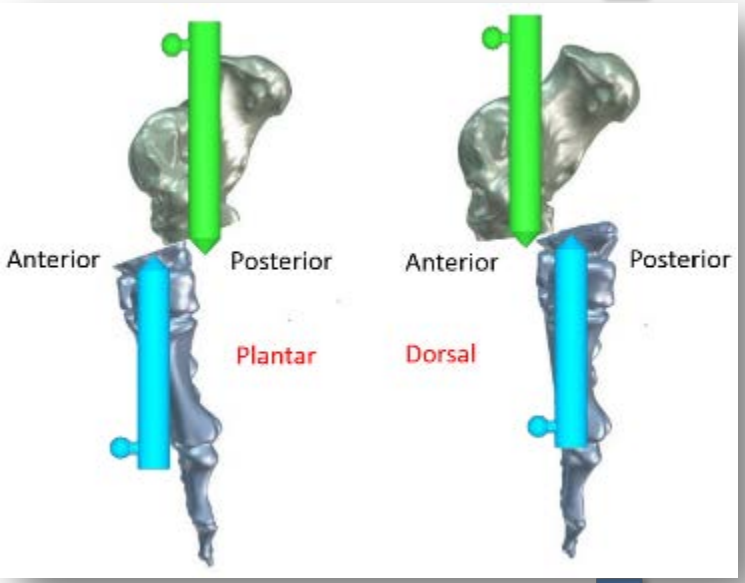

TRANSLATION DORSAL
(anterior translation)

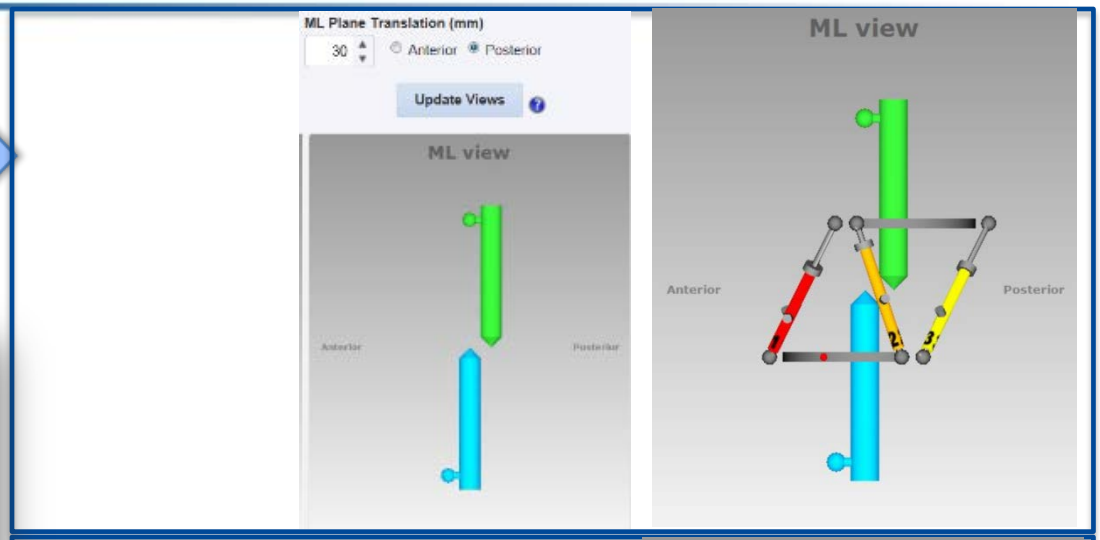

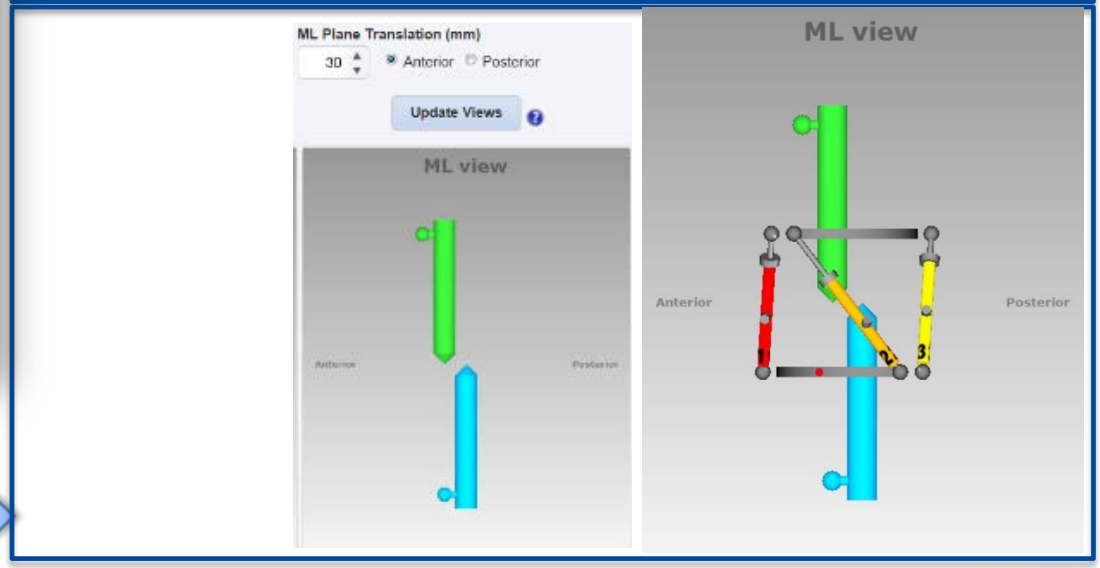

AXIAL VIEW (5/8 Rings)

RIGHT FOOT

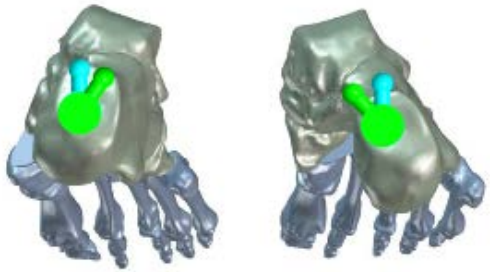

Rotation (deg) 45 External Internal

Axial Translation (mm) 0 Short Long

Bone Length (mm) 0 Short Long

Axial view

Anterior

Medial Lateral

Posterior

Forefoot Pronation

Forefoot Supination

SW Axial View is from Prox. Segment

Rotation (deg) 45 External Internal

Axial Translation (mm) 0 Short Long

Bone Length (mm) 0 Short Long

Axial view

Anterior

Medial Lateral

Posterior

ORTHOFIX

Full Rings

5/8 Rings

BACK

ORTHOFIX

LEFT FOOT Anatomical – Forefoot (Reference segment Distal) with Full Rings

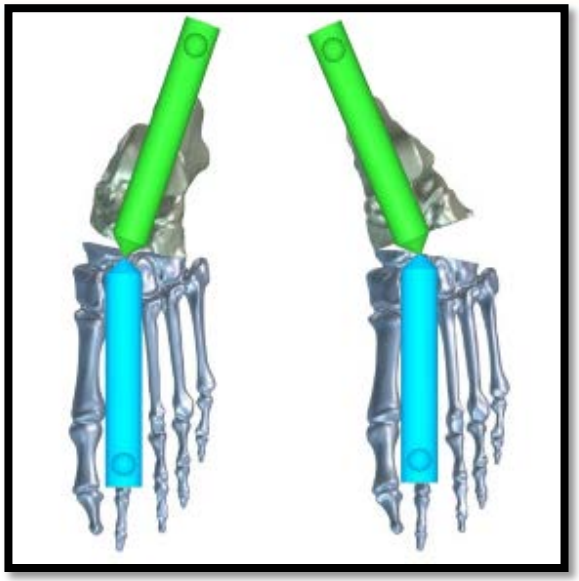

Valgus Varus

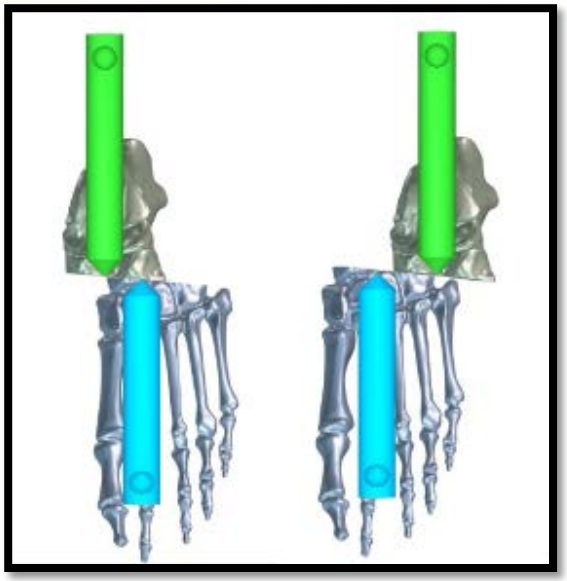

Medial Lateral

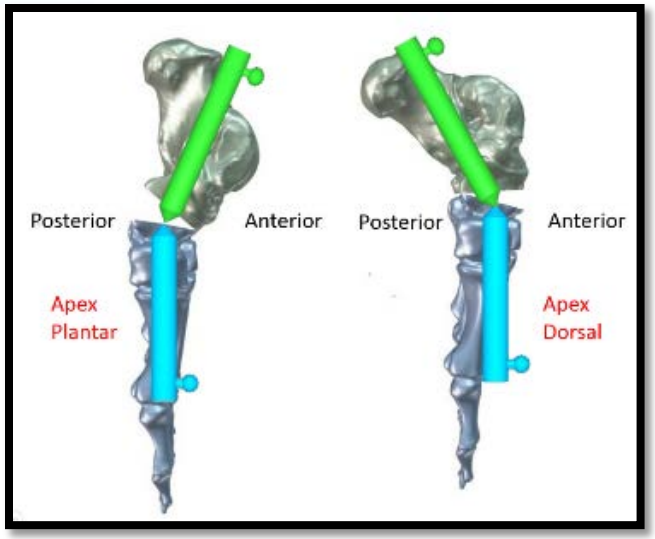

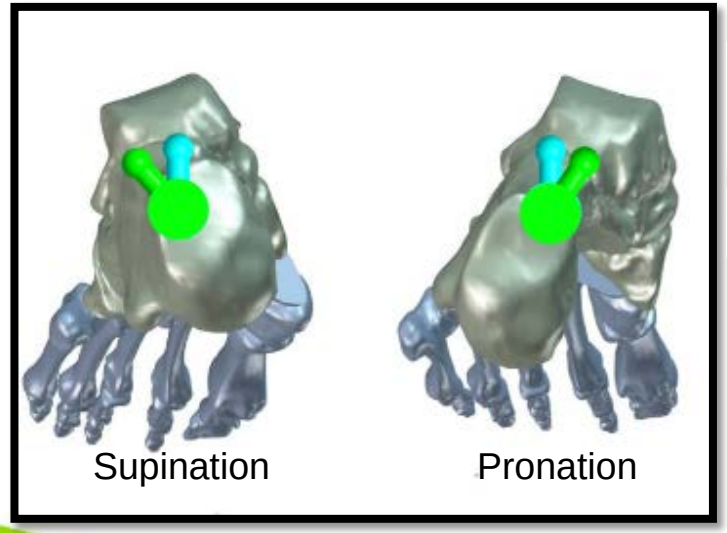

Supination Pronation

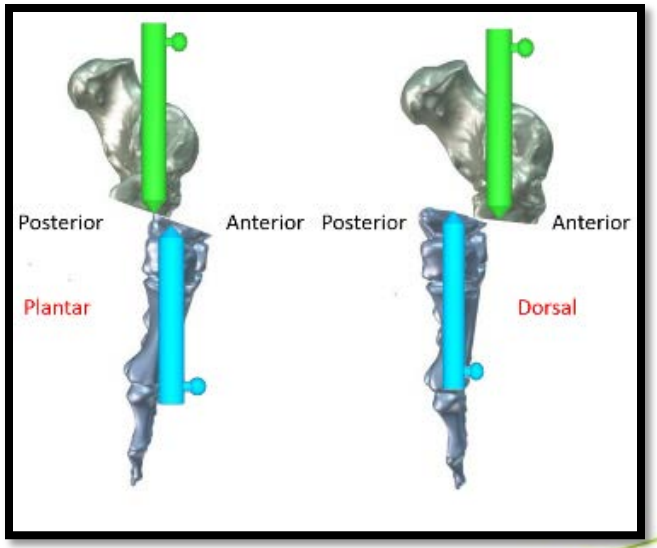

Click on Image

ORTHOFIX

AP View deformity inputs (Full Rings)

LEFT FOOT

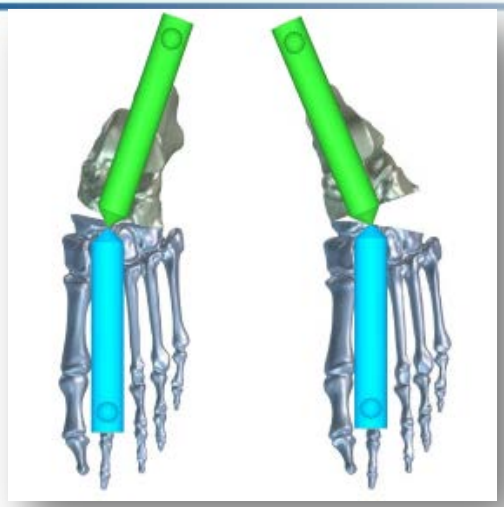

Anatomical Valgus

Anatomical Varus

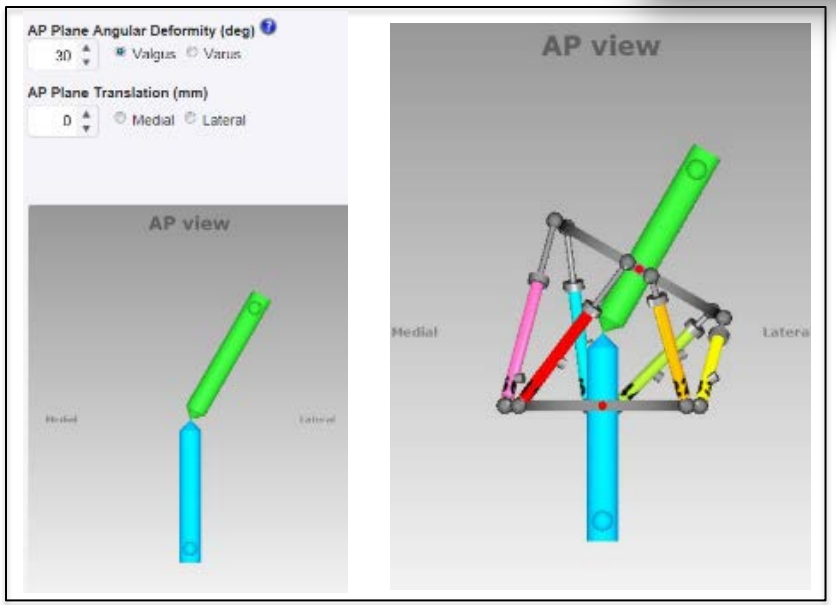

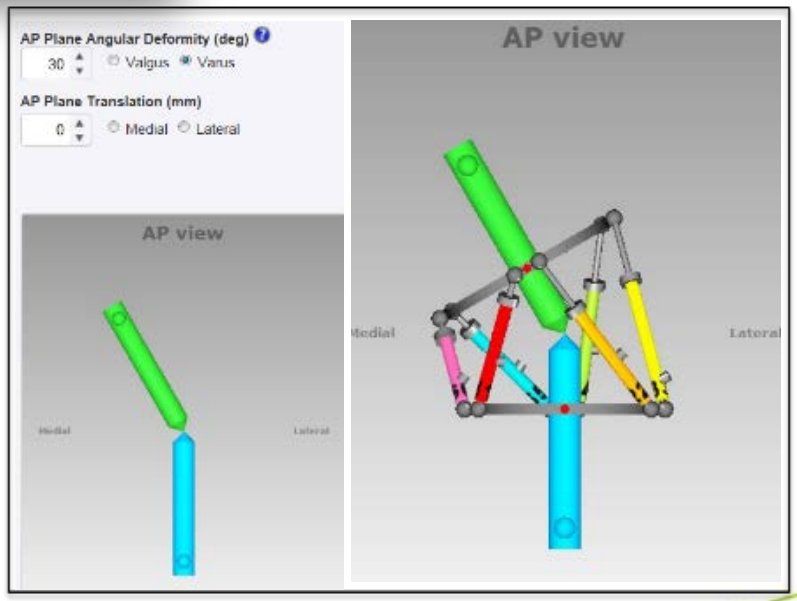

AP View deformity inputs (Full Rings)

LEFT FOOT

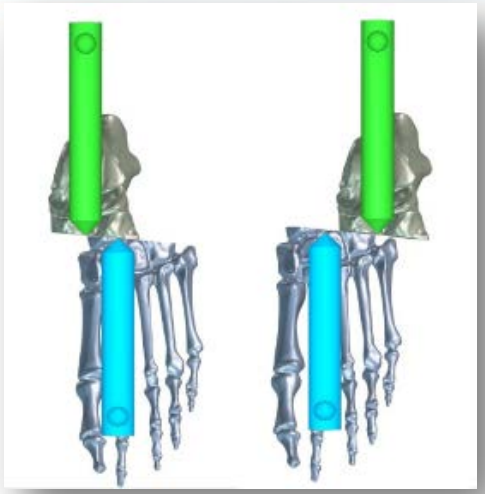

Anatomical
Medial

Anatomical
Lateral

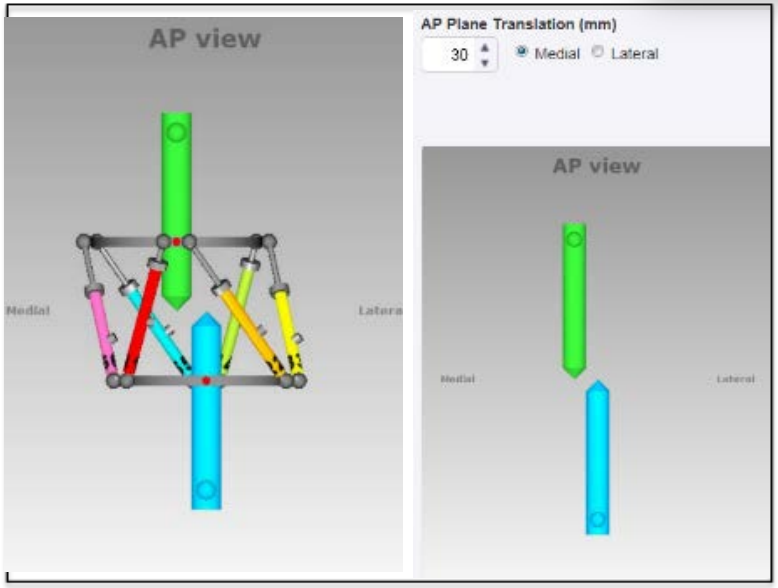

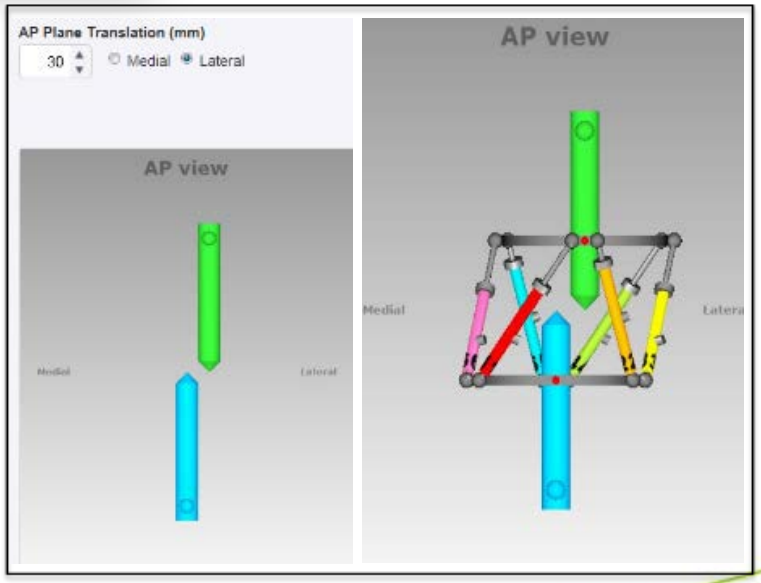

LATERAL VIEW – ANGULATION (Full Rings)

LEFT FOOT

APEX
POSTERIOR/PLANTAR
(Recurvatum)

Xray Medial

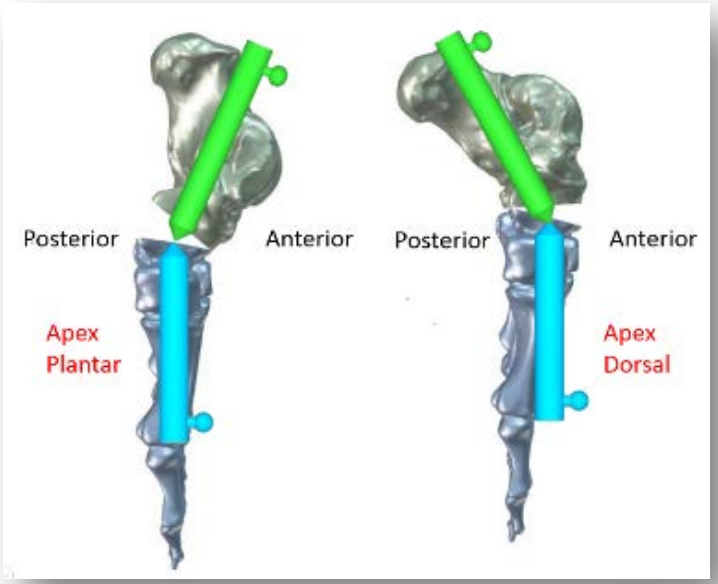

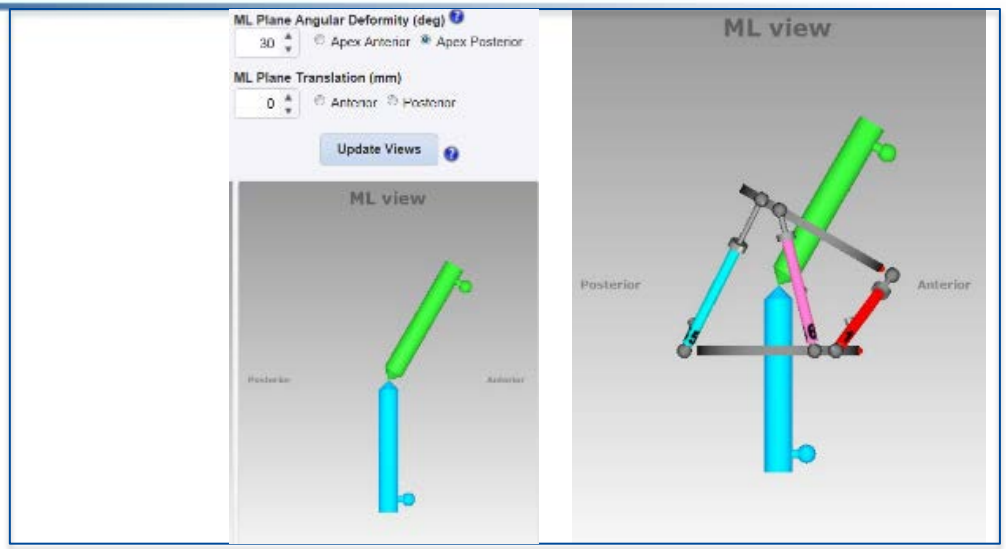

APEX
ANTERIOR/DORSAL
(Procurvatum)

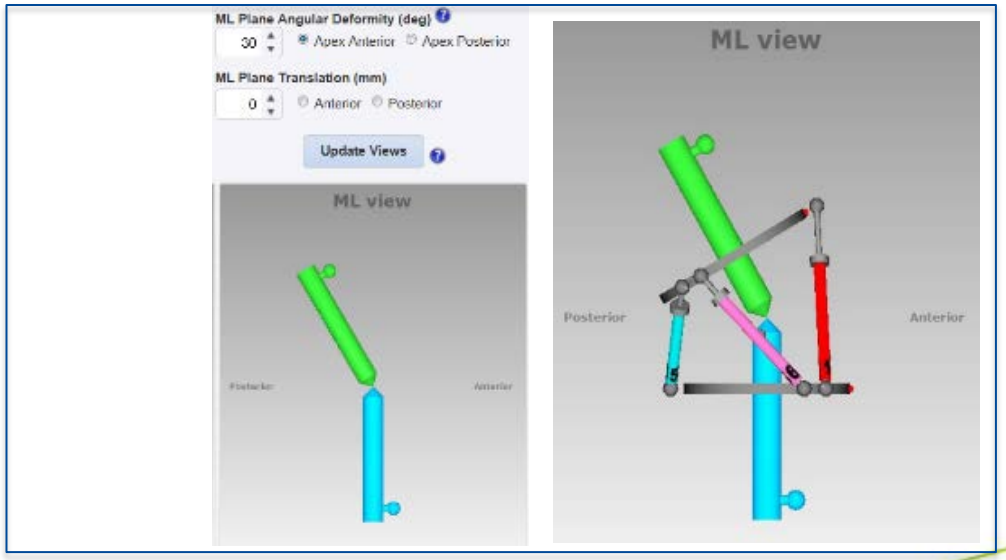

ORTHOFIX

LATERAL VIEW – TRANSLATION (Full Rings)

LEFT FOOT

TRANSLATION PLANTAR
(posterior translation)

Xray Medial

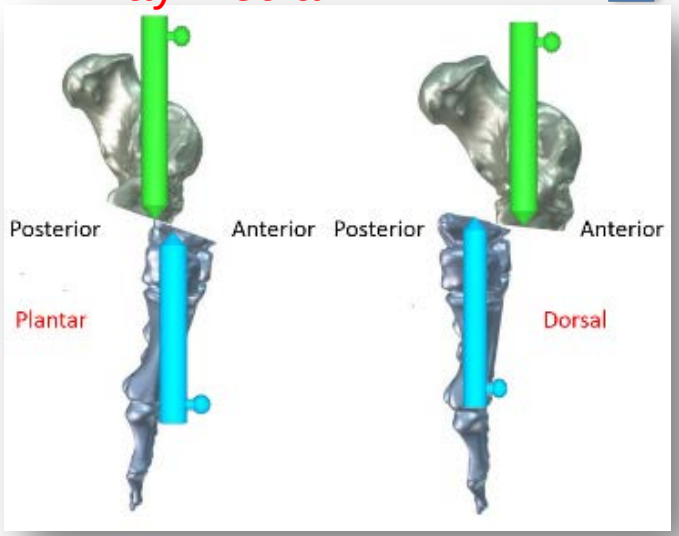

TRANSLATION DORSAL
(anterior translation)

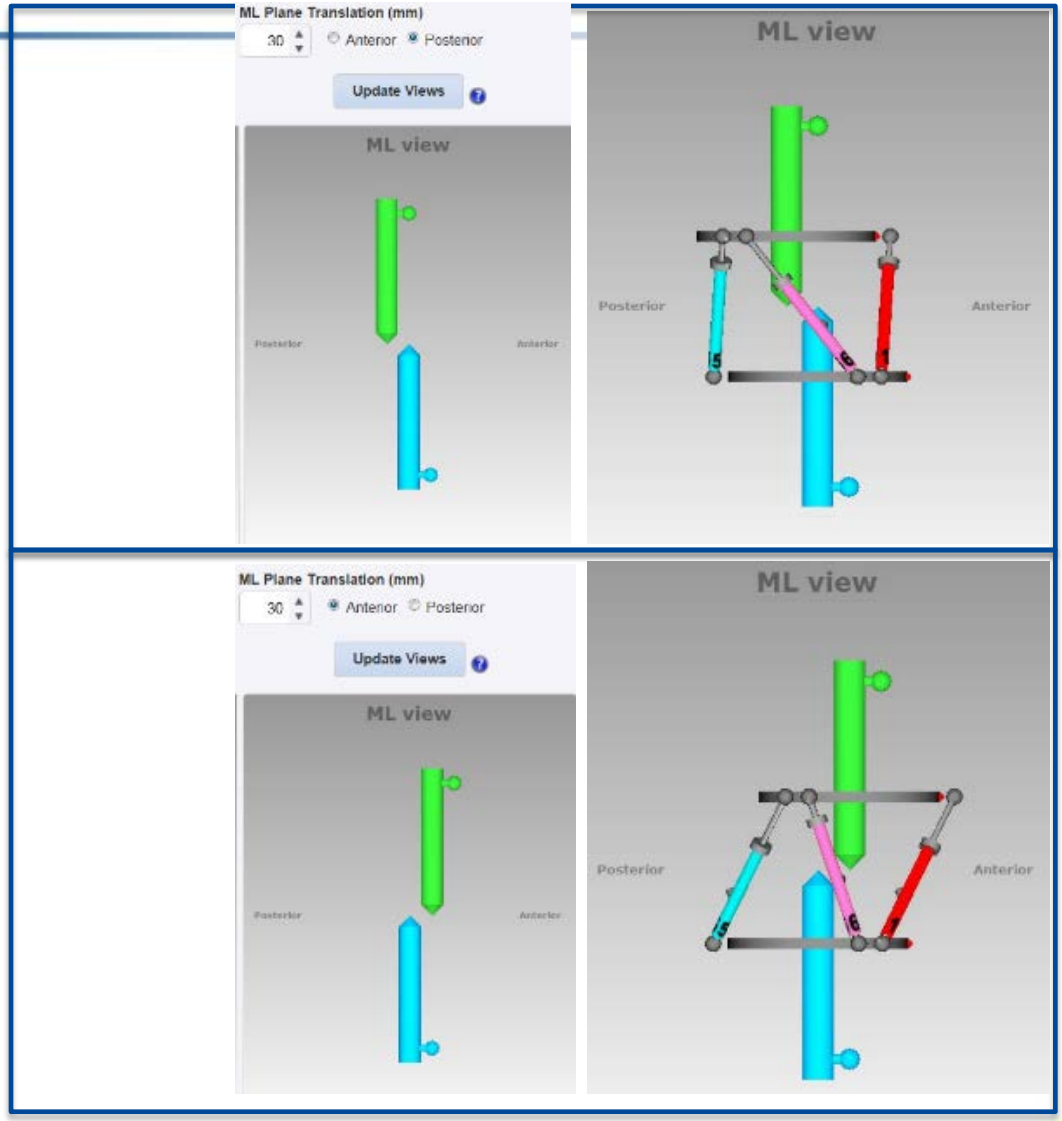

AXIAL VIEW (Full Rings)

LEFT FOOT

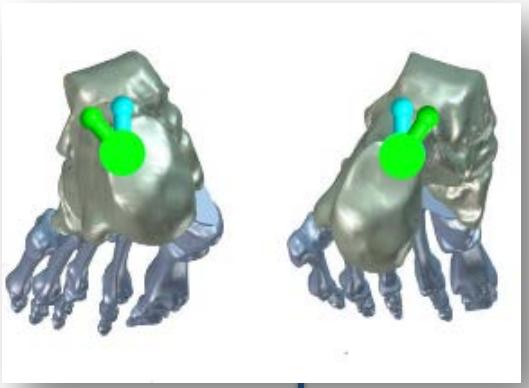

Rotation (deg) 45 External Internal

Axial Translation (mm) 0 Short Long

Bone Length (mm) 0 Short Long



Forefoot Pronation

Forefoot Supination

SW Axial View is from Prox. Segment

Rotation (deg) 45 External Internal

Axial Translation (mm) 0 Short Long

Bone Length (mm) 0 Short Long

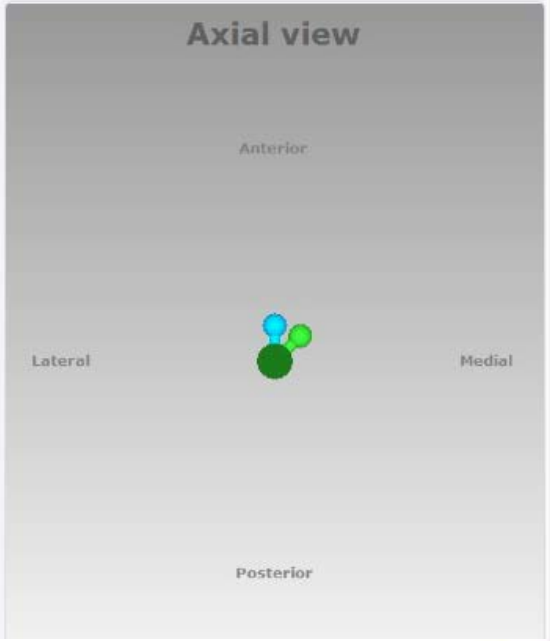

ORTHOFIX

LEFT FOOT Anatomical – Forefoot (Reference segment Distal) with 5/8 Rings

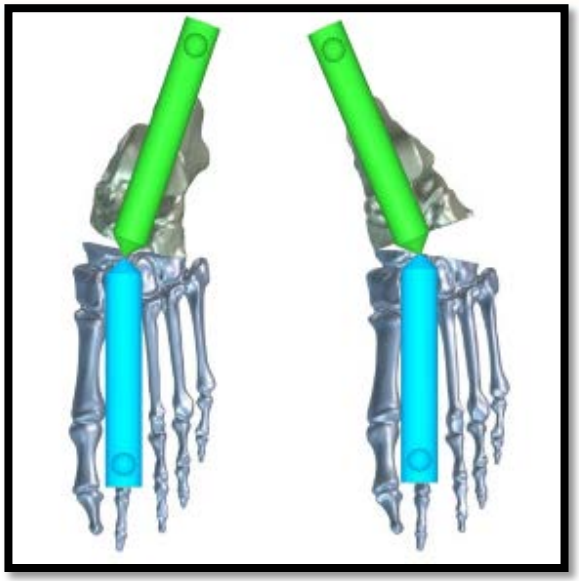

Valgus Varus

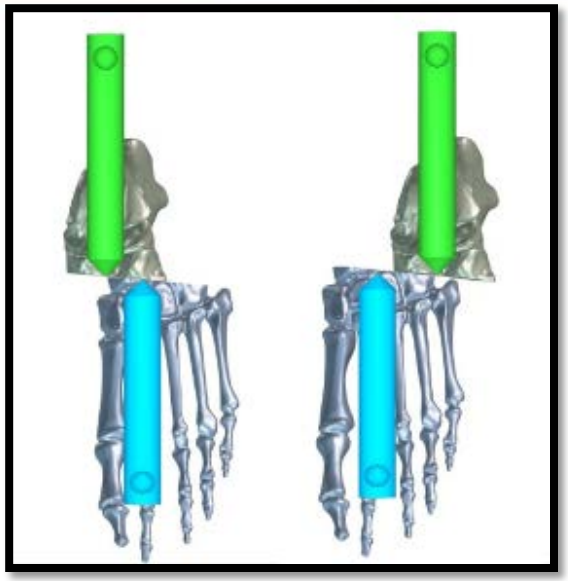

Medial Lateral

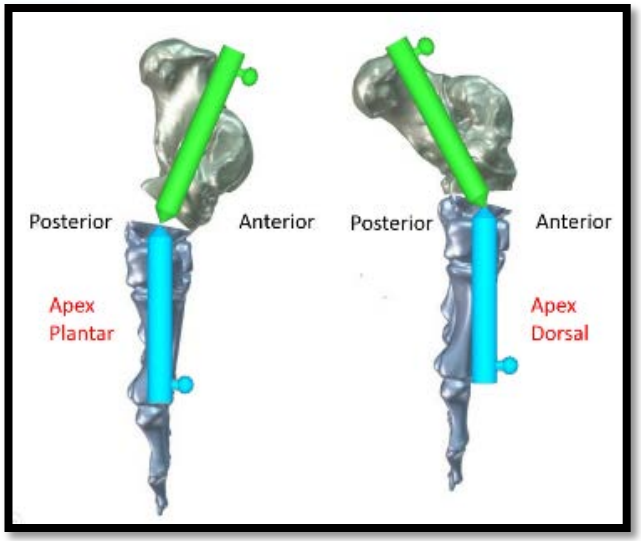

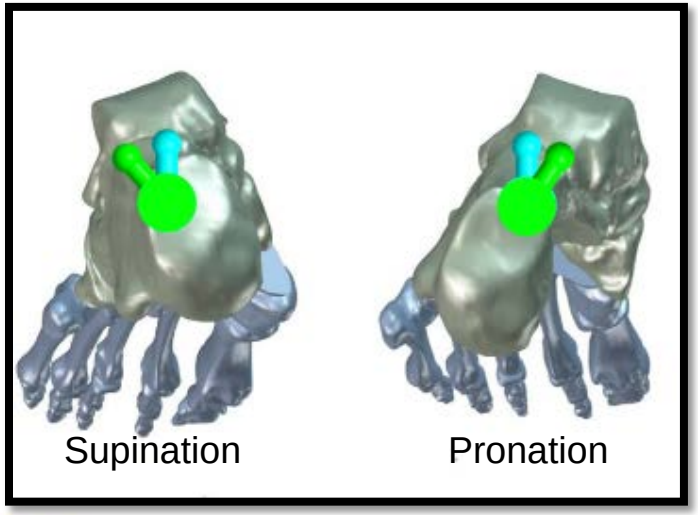

Supination Pronation

Click on Image

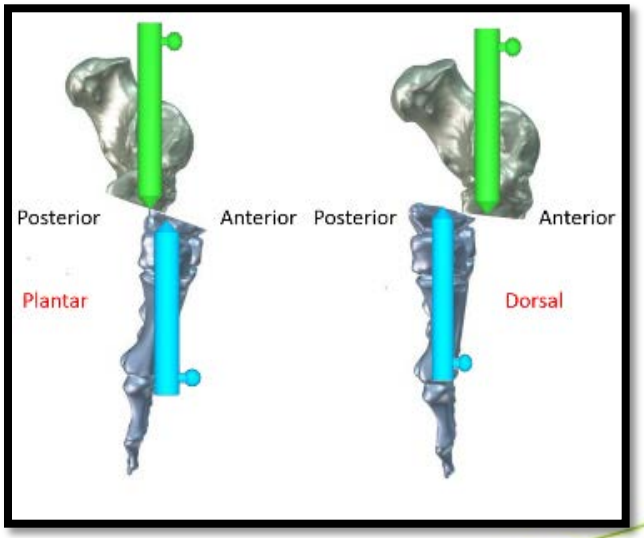

ORTHOFIX

AP View deformity inputs (5/8 Rings)

LEFT FOOT

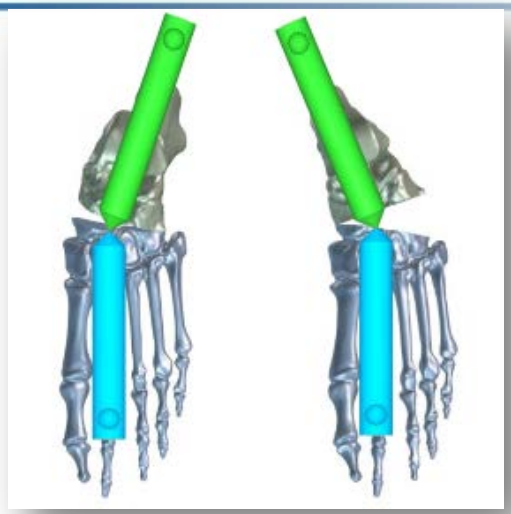

Anatomical Valgus

Anatomical Varus

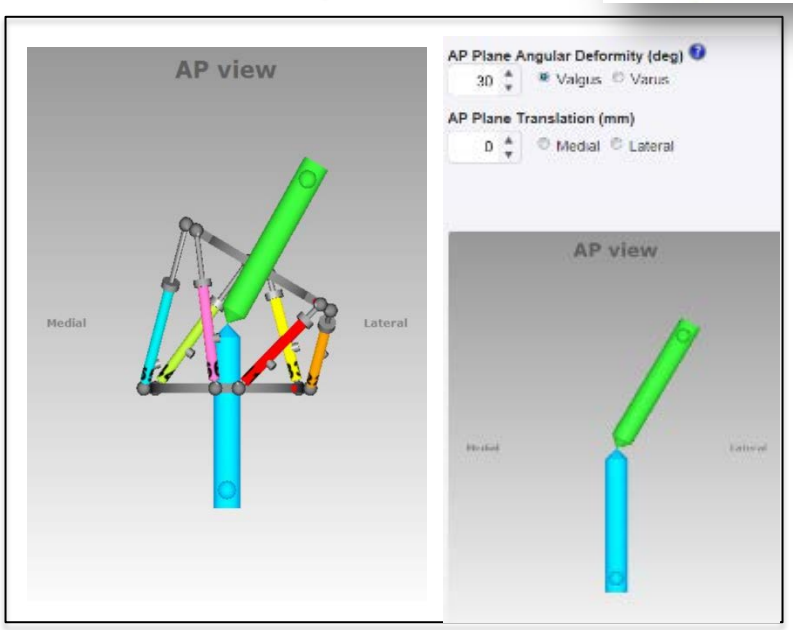

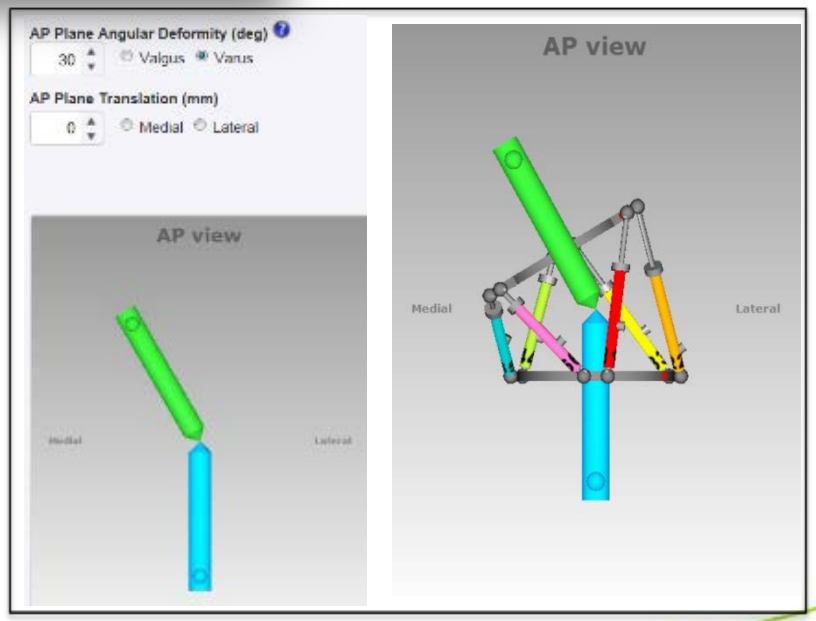

AP View deformity inputs (5/8 Rings)

LEFT FOOT

Anatomical
Medial

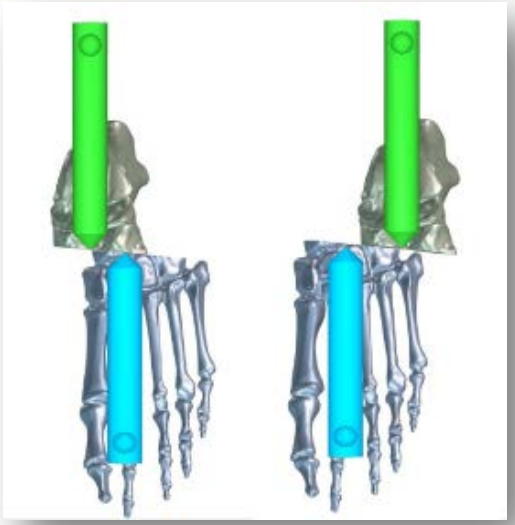

Anatomical
Lateral

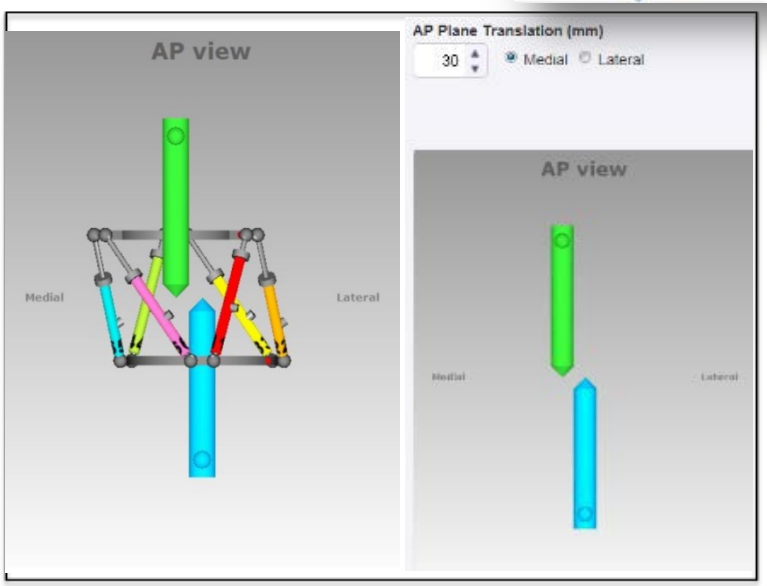

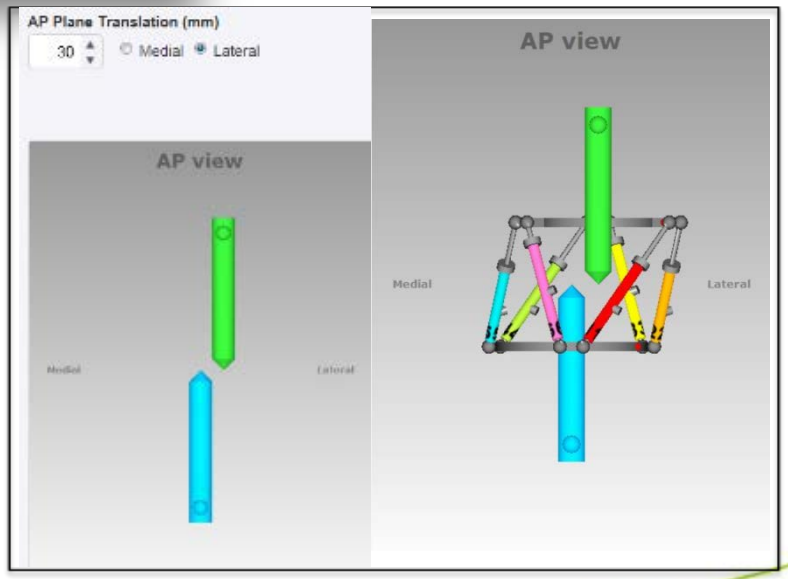

LATERAL VIEW – ANGULATION (5/8 Rings)

LEFT FOOT

APEX
POSTERIOR/PLANTAR
(Recurvatum)

Xray Medial

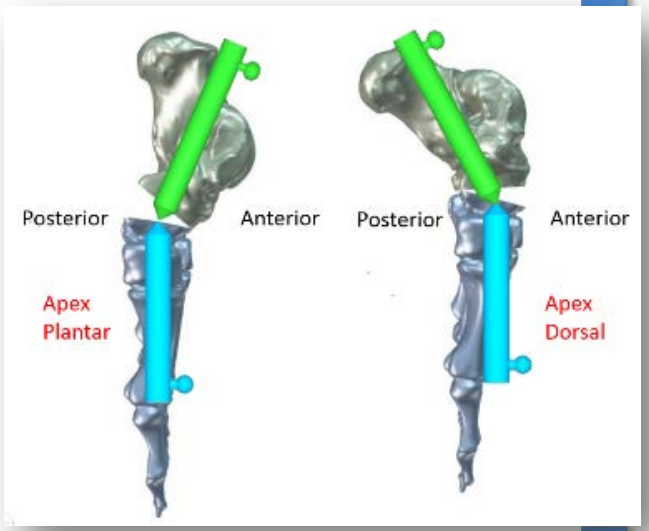

APEX
ANTERIOR/DORSAL
(Procurvatum)

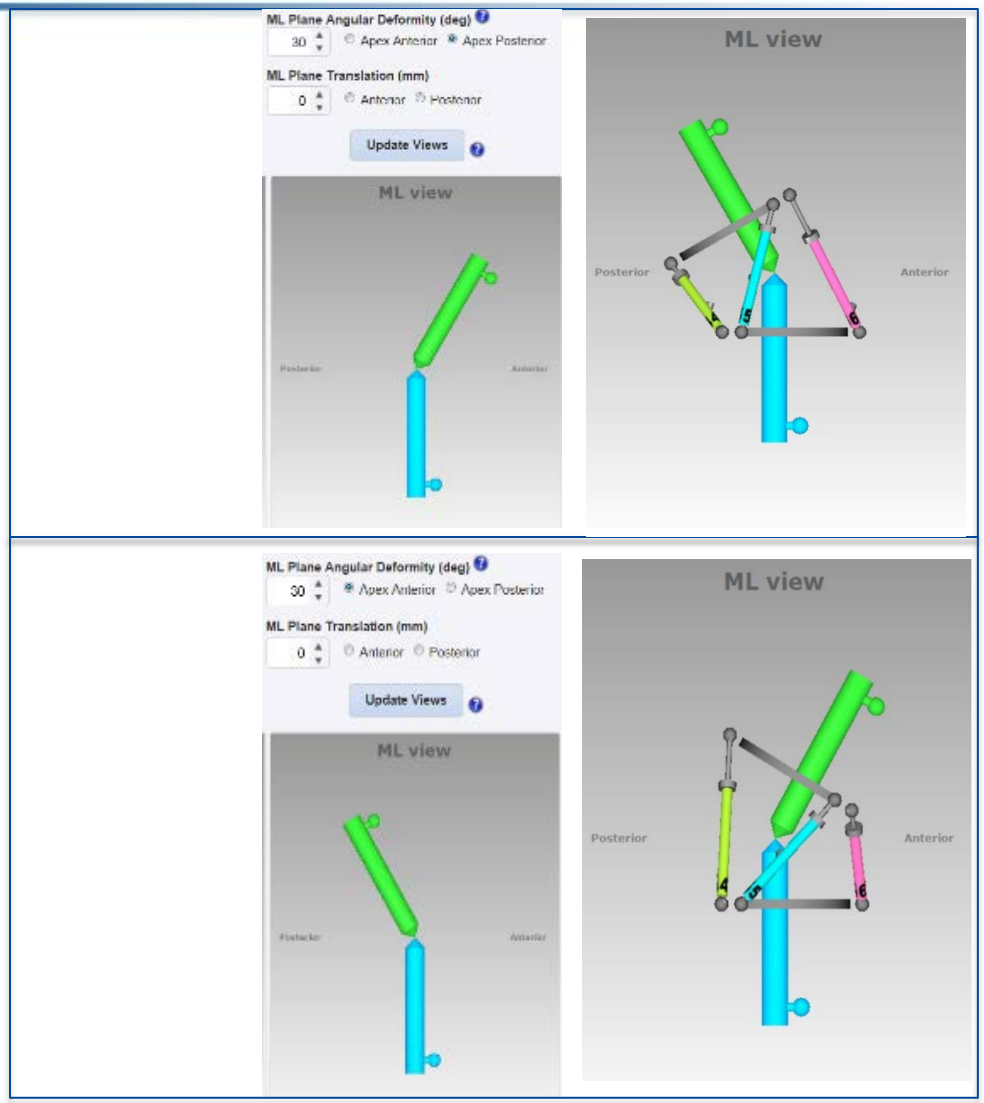

LATERAL VIEW – TRANSLATION (5/8 Rings)

LEFT FOOT

TRANSLATION PLANTAR
(posterior translation)

Xray Medial

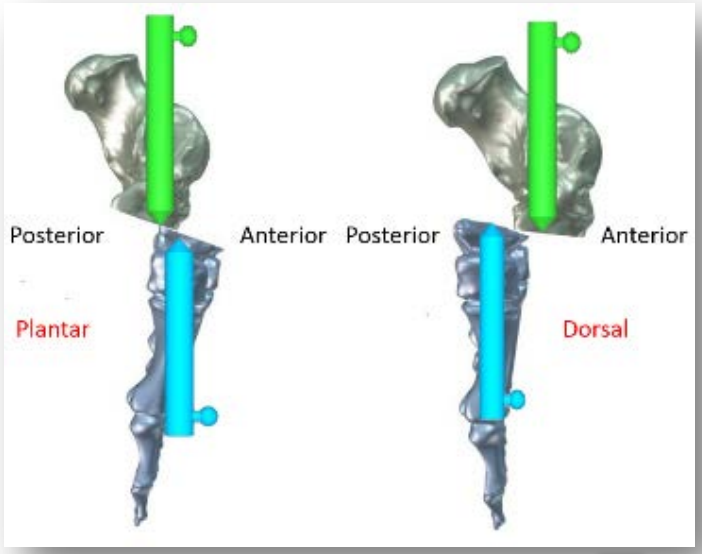

TRANSLATION DORSAL
(anterior translation)

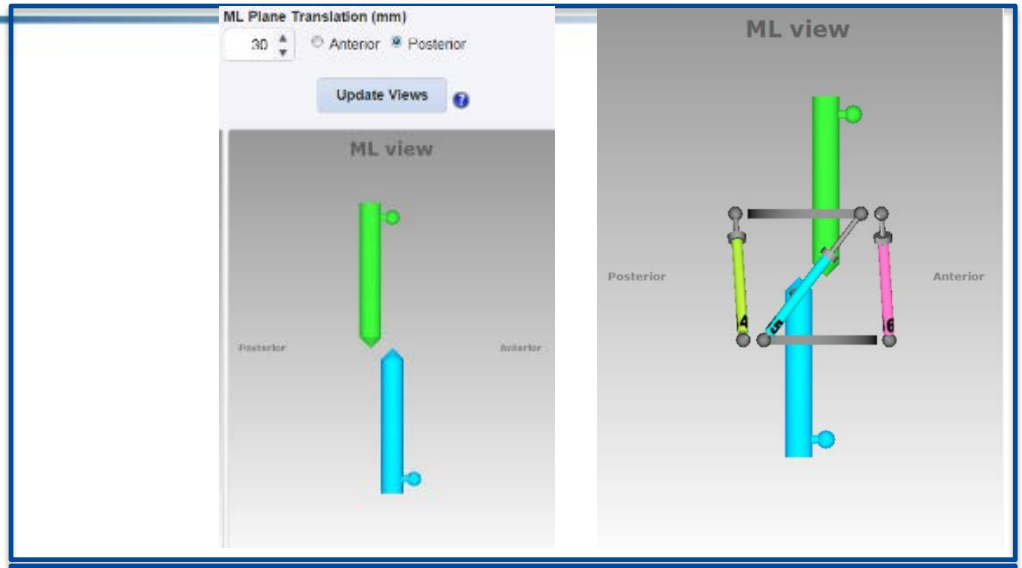

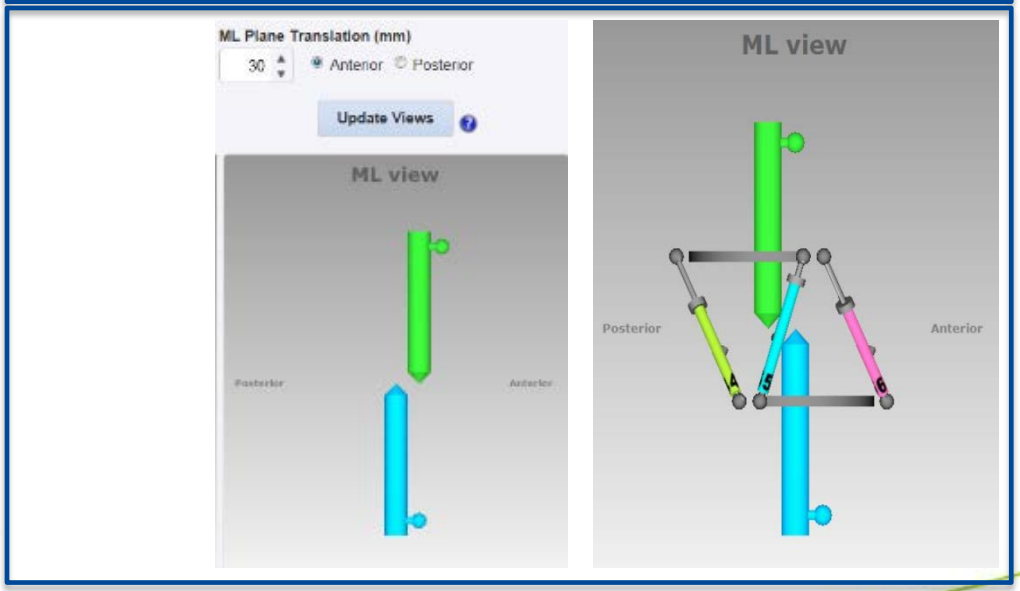

AXIAL VIEW (5/8 Rings)

LEFT FOOT

Rotation (deg) 45 External Internal

Axial Translation (mm) 0 Short Long

Bone Length (mm) 0 Short Long



Forefoot Pronation

Forefoot Supination

SW Axial View is from Prox. Segment

Rotation (deg) 45 External Internal

Axial Translation (mm) 0 Short Long

Bone Length (mm) 0 Short Long



ORTHOFIX

AP VIEW (Hindfoot)

Right Foot

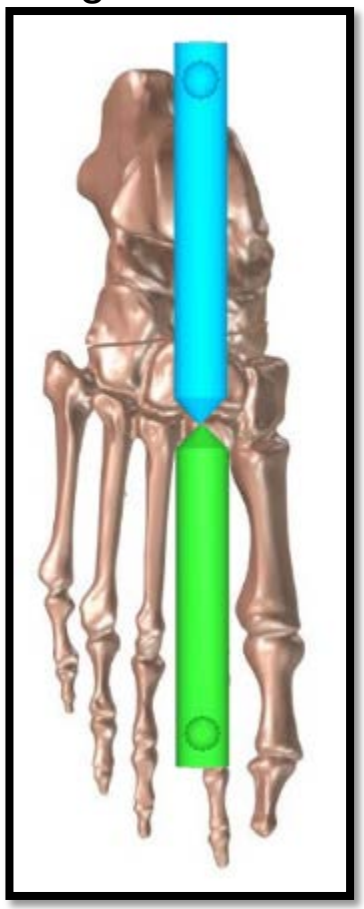

Left Foot

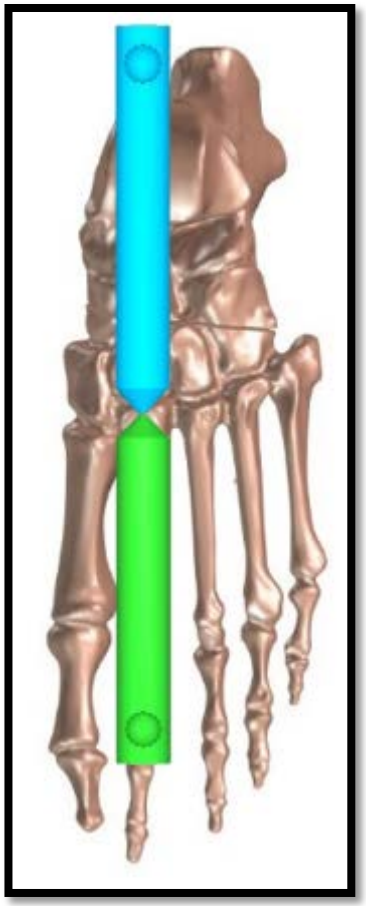

Click on Image

ORTHOFIX

Full Rings

5/8 Rings

BACK

ORTHOFIX

RIGHT FOOT Anatomical –Hindfoot (Reference segment Prox) with Full Rings

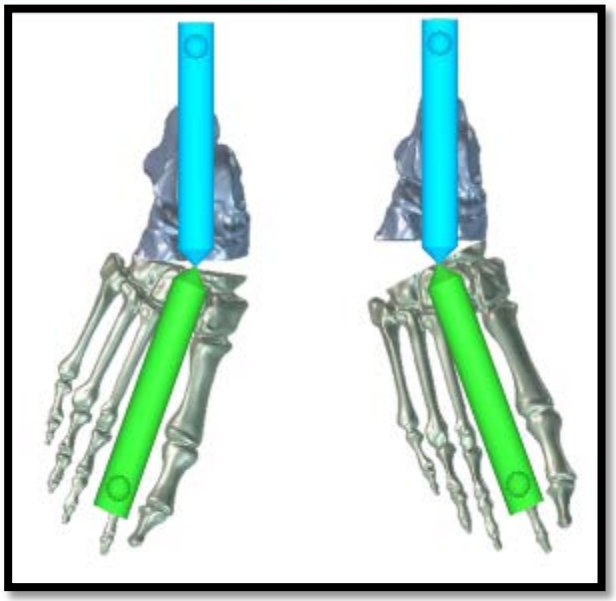

Valgus Varus



Lateral Medial

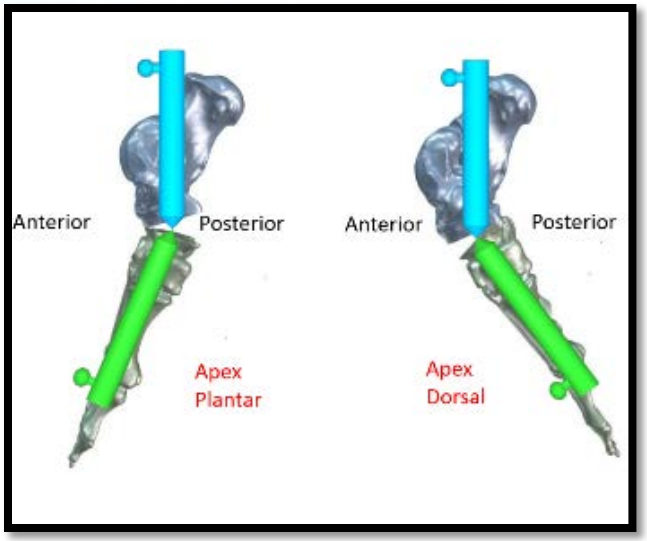

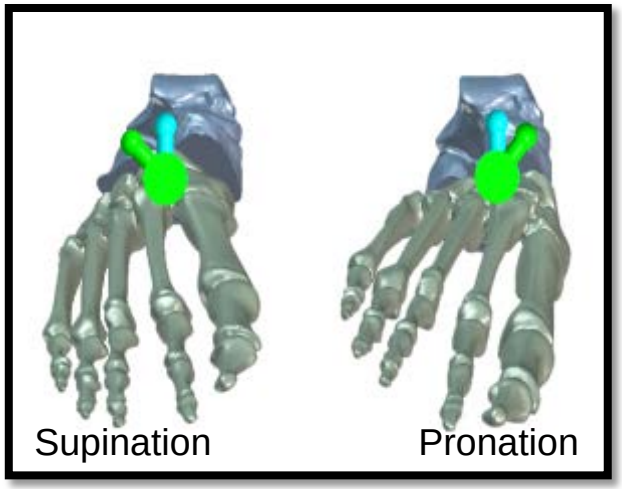

Supination Pronation

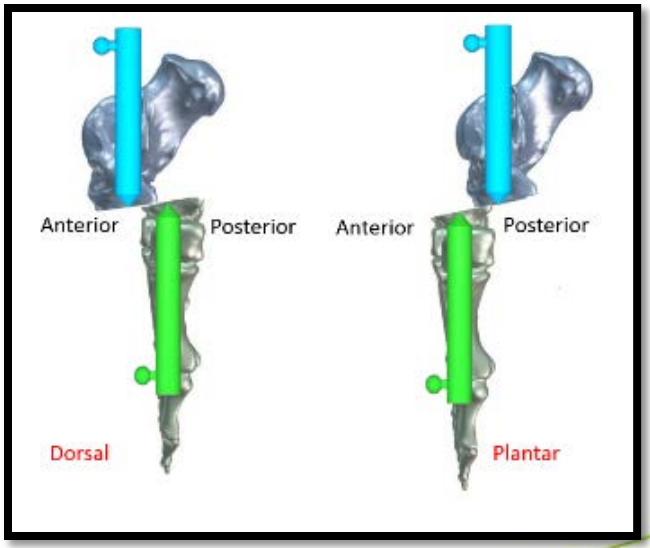

Click on Image

ORTHOFIX

AP View deformity inputs (Full Rings)

RIGHT FOOT

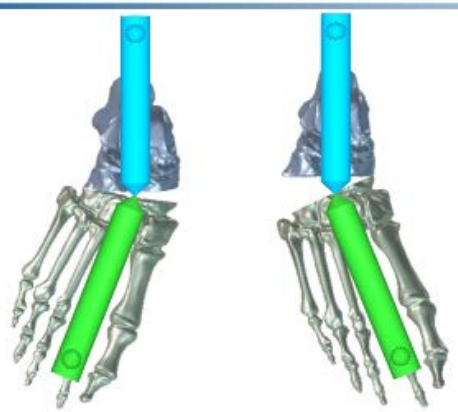

Valgus

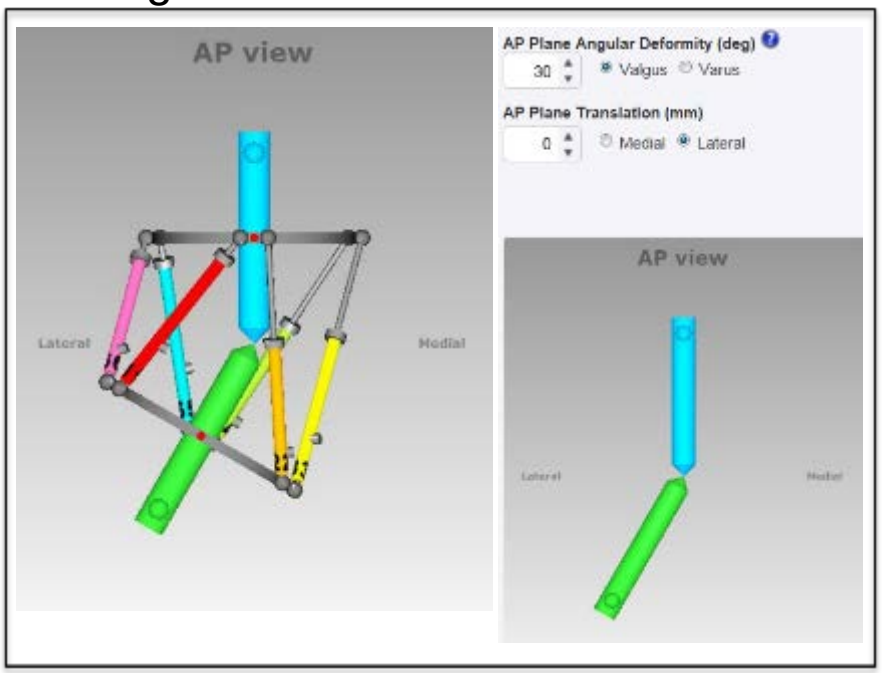

Varus

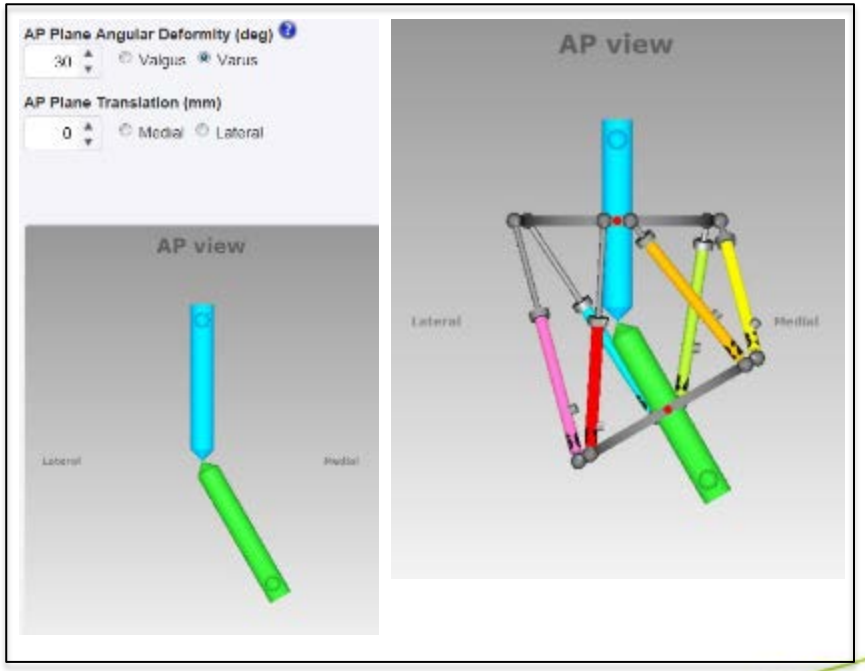

AP View deformity inputs (Full Rings)

RIGHT FOOT

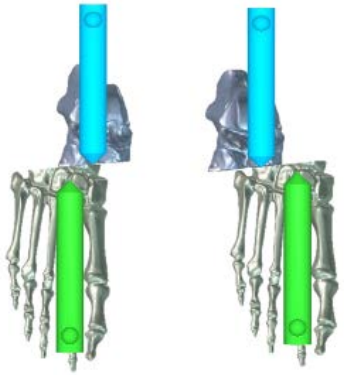

Lateral

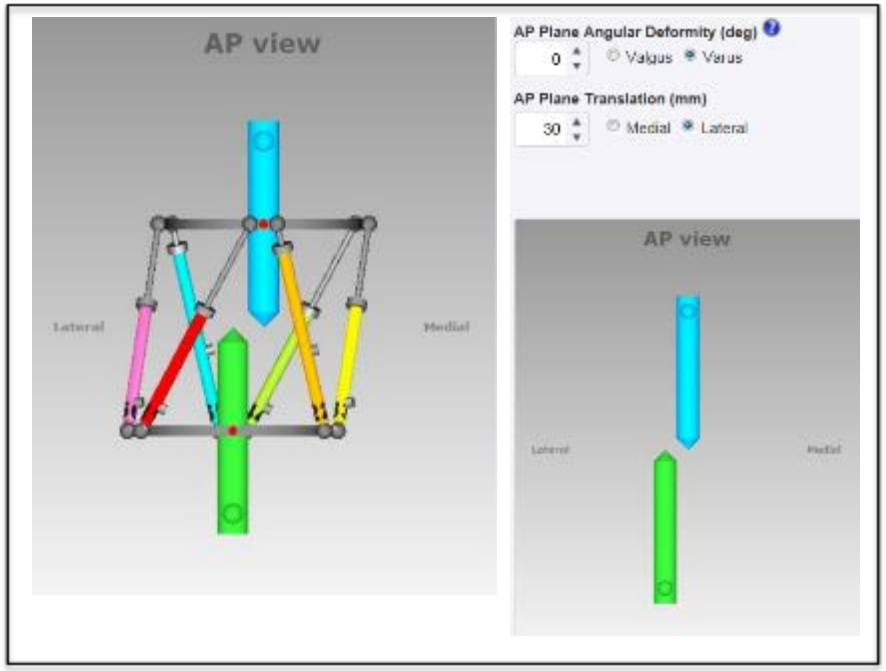

Medial

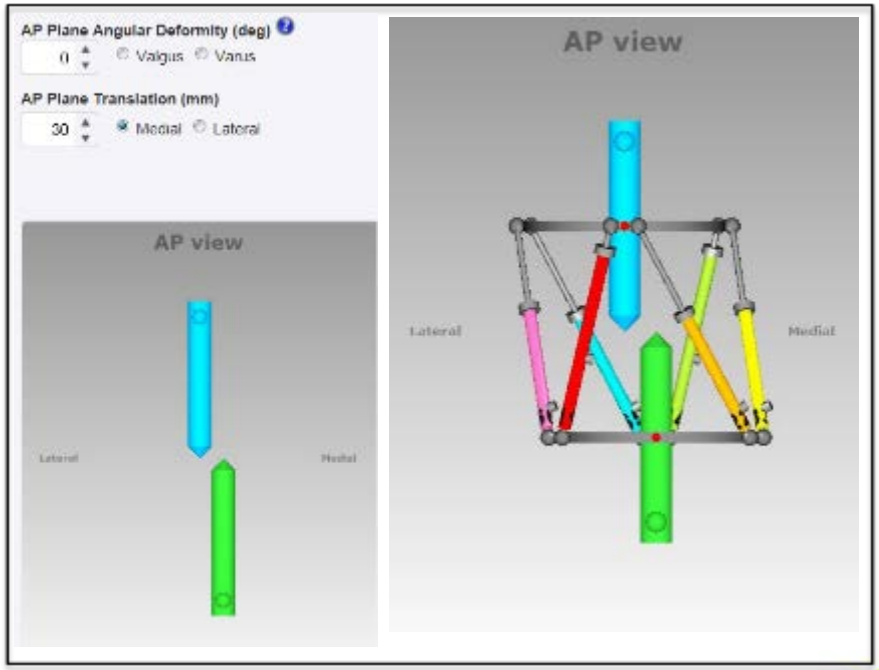

LATERAL VIEW – ANGULATION (Full Rings)

RIGHT FOOT

APEX
POSTERIOR/PLANTAR
(Recurvatum)

Xray Medial

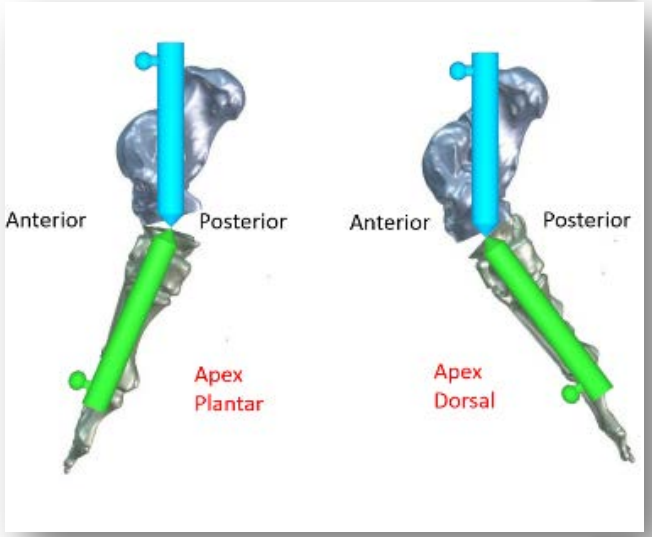

APEX
ANTERIOR/DORSAL
(Procurvatum)

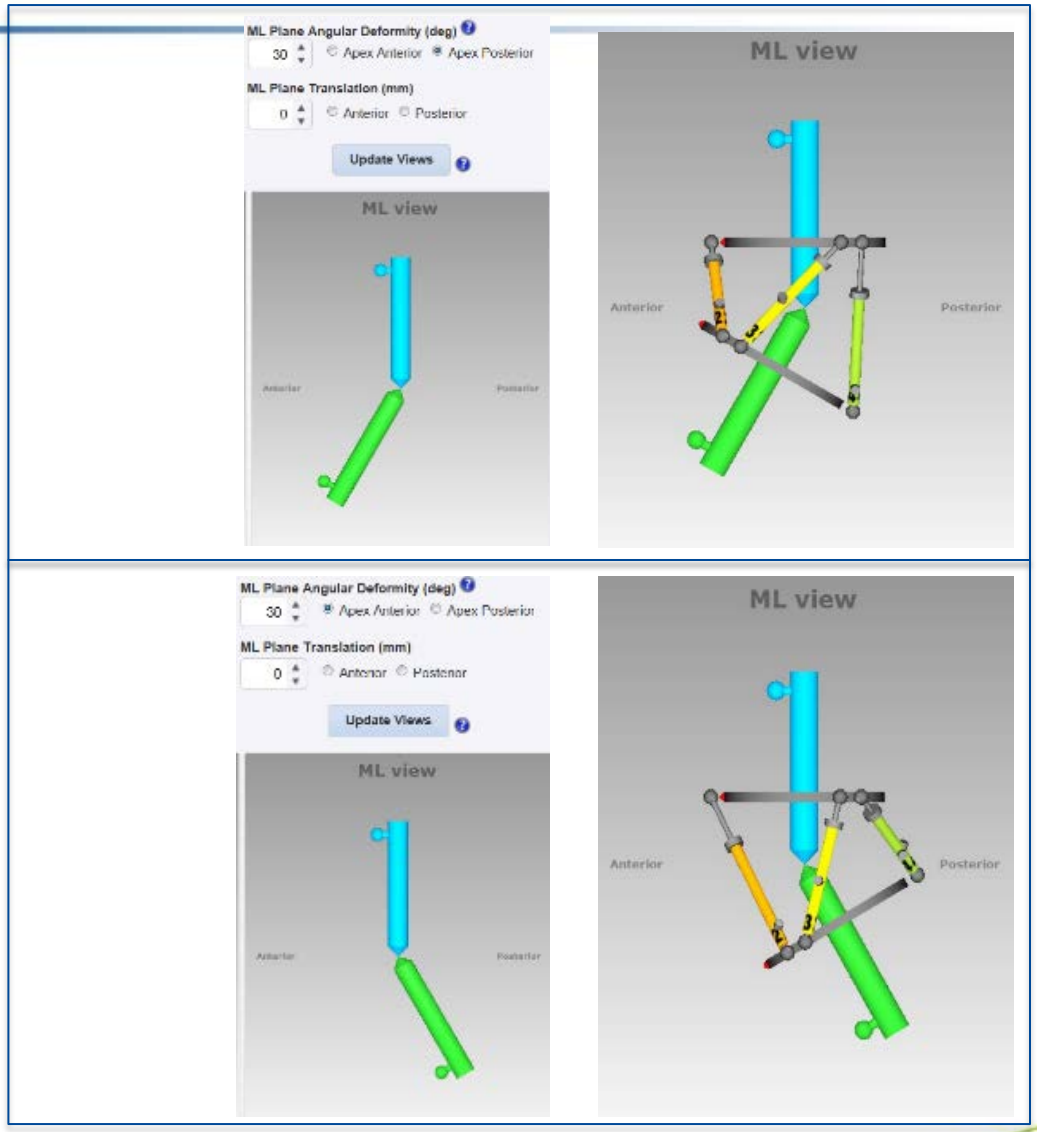

ORTHOFIX

LATERAL VIEW – TRANSLATION (Full Rings)

RIGHT FOOT

TRANSLATION PLANTAR
(anterior translation)

Xray Medial

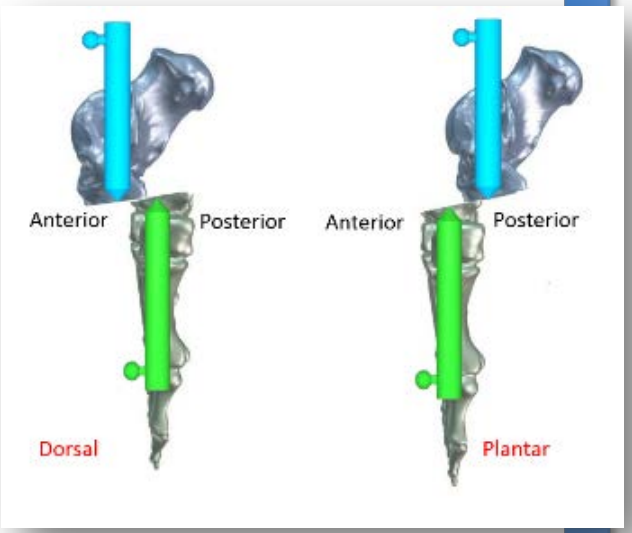

TRANSLATION DORSAL
(posterior translation)

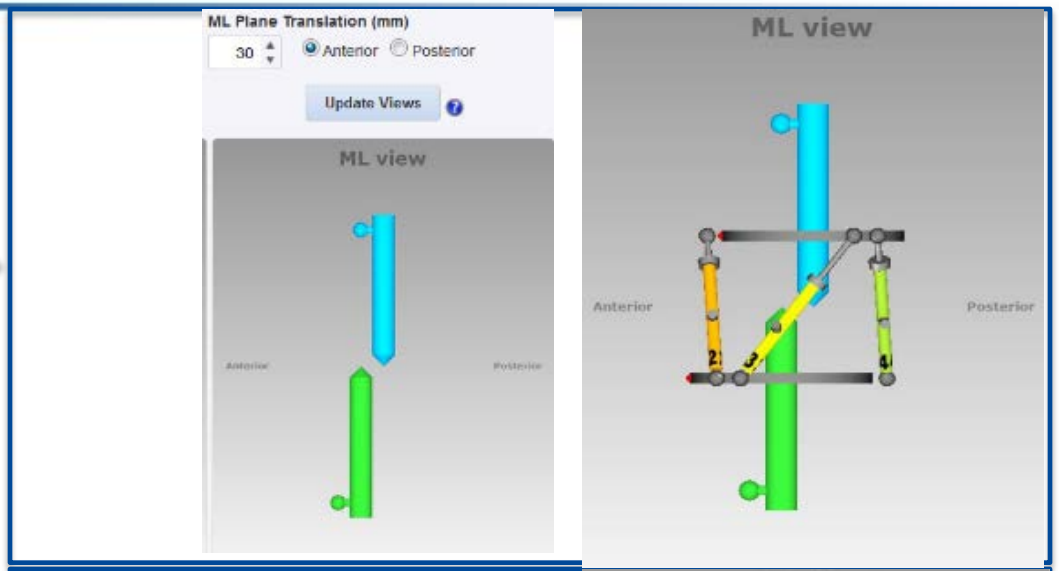

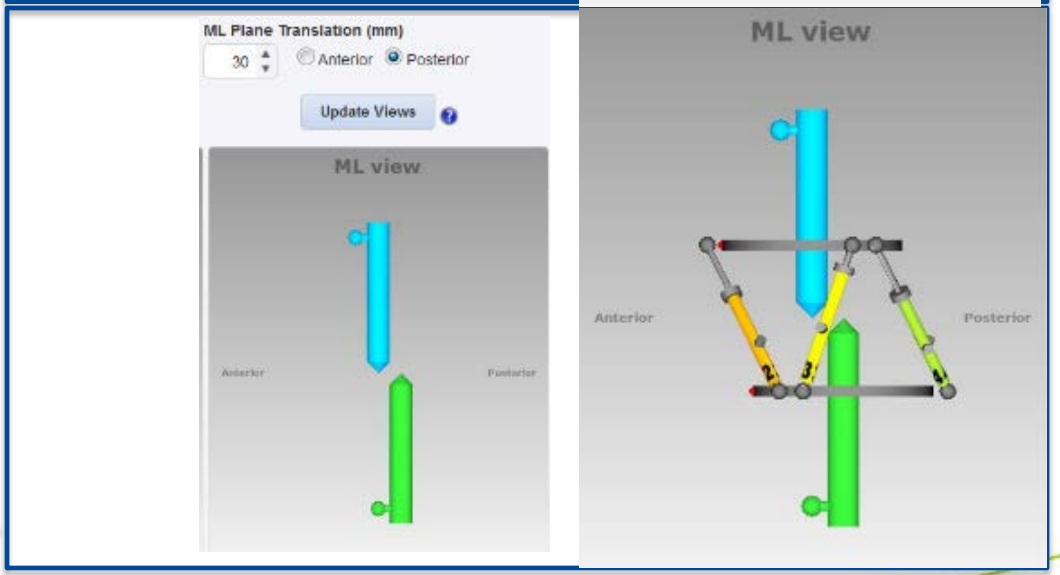

AXIAL VIEW (Full Rings)

Rotation (deg) 45 External Internal

Axial Translation (mm) 0 Short Long

Bone Length (mm) 0 Short Long

Axial view

Anterior

Medial Lateral

Posterior

RIGHT FOOT

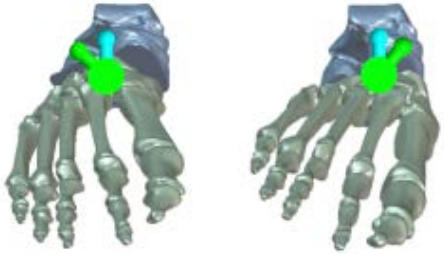

Hindfoot Pronation

INTERNAL ROTATION

Hindfoot Supination

EXTERNAL ROTATION

Rotation (deg) 45 External Internal

Axial Translation (mm) 0 Short Long

Bone Length (mm) 0 Short Long

Axial view

Anterior

Medial Lateral

Posterior

ORTHOFIX

RIGHT FOOT Anatomical –Hindfoot (Reference segment Prox) with 5/8 Rings

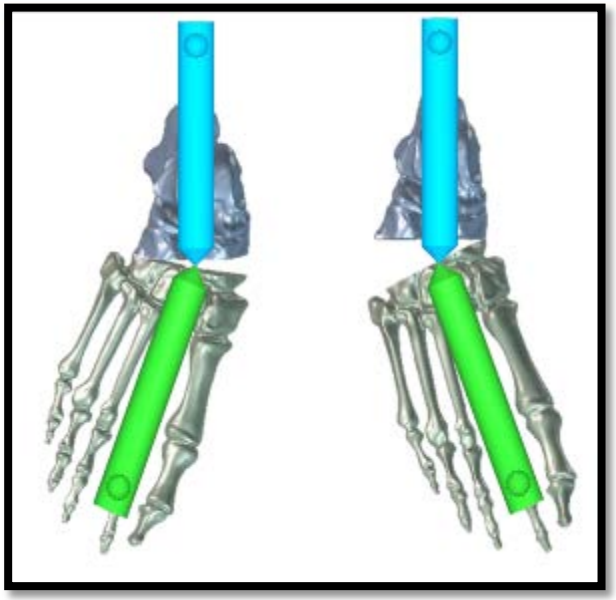

Valgus Varus



Lateral Medial

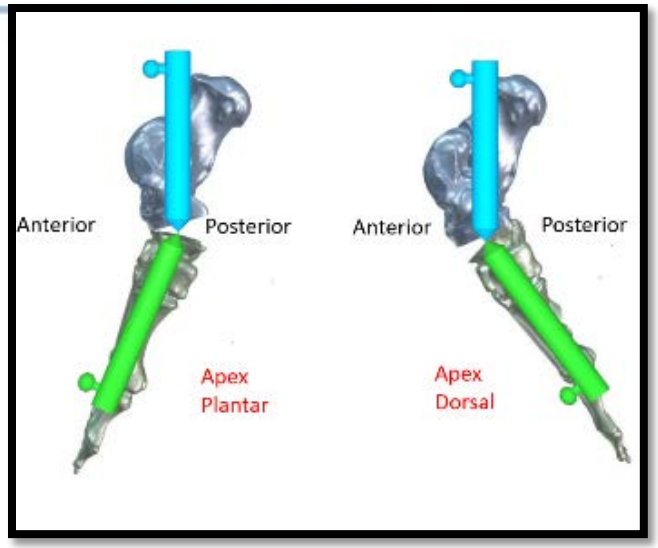

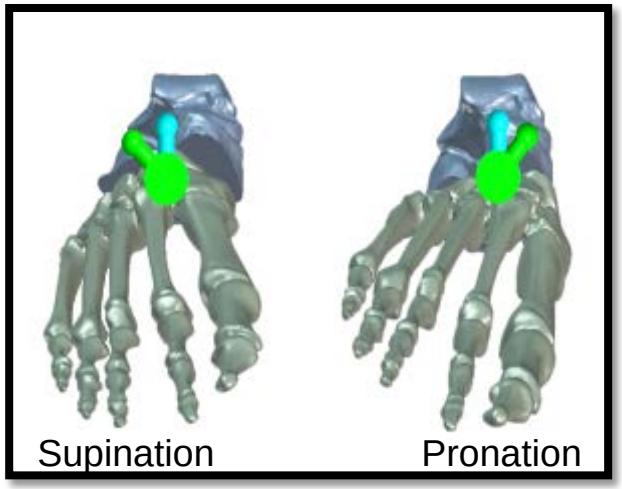

Supination Pronation

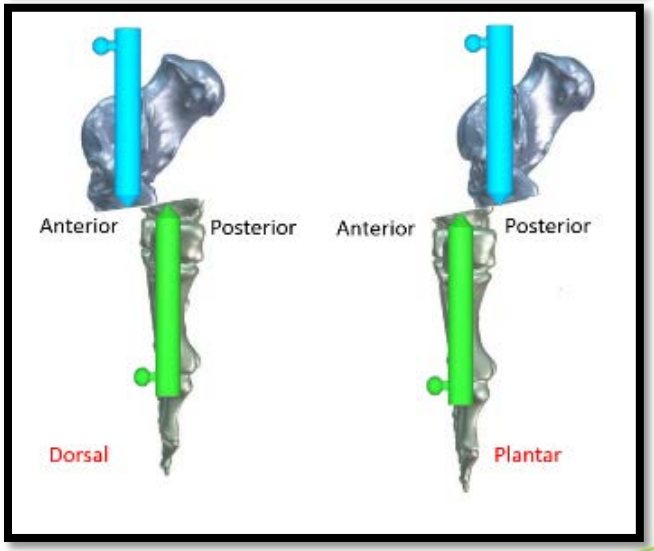

Click on Image

ORTHOFIX

AP View deformity inputs (5/8 Rings)

RIGHT FOOT

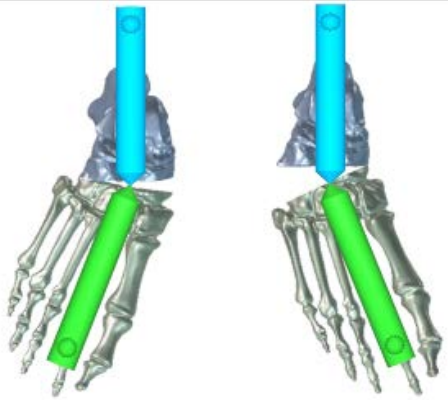

Valgus

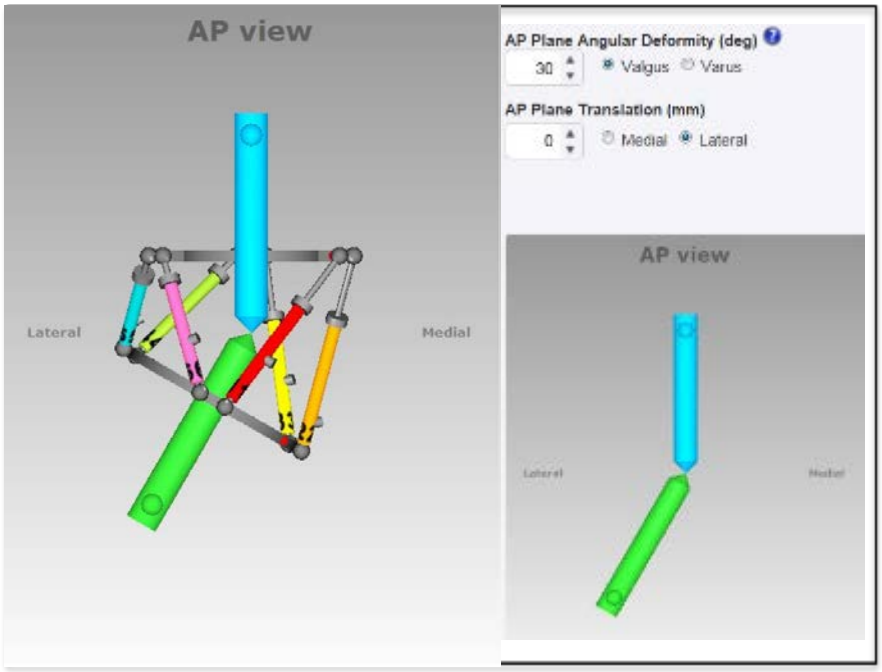

Varus

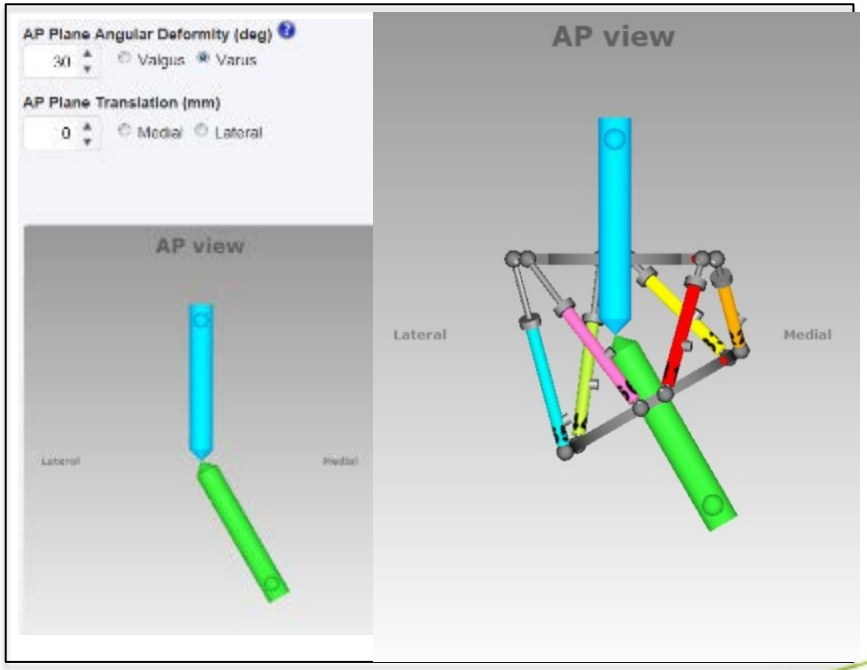

ORTHOFIX

AP View deformity inputs (5/8 Rings)

RIGHT FOOT

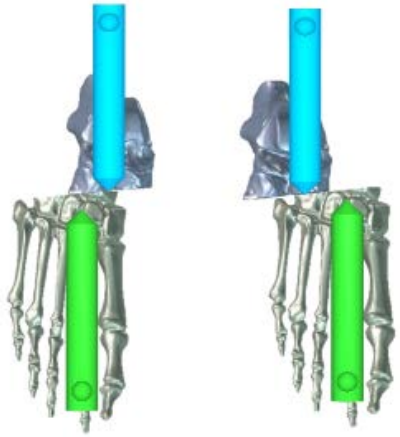

Lateral

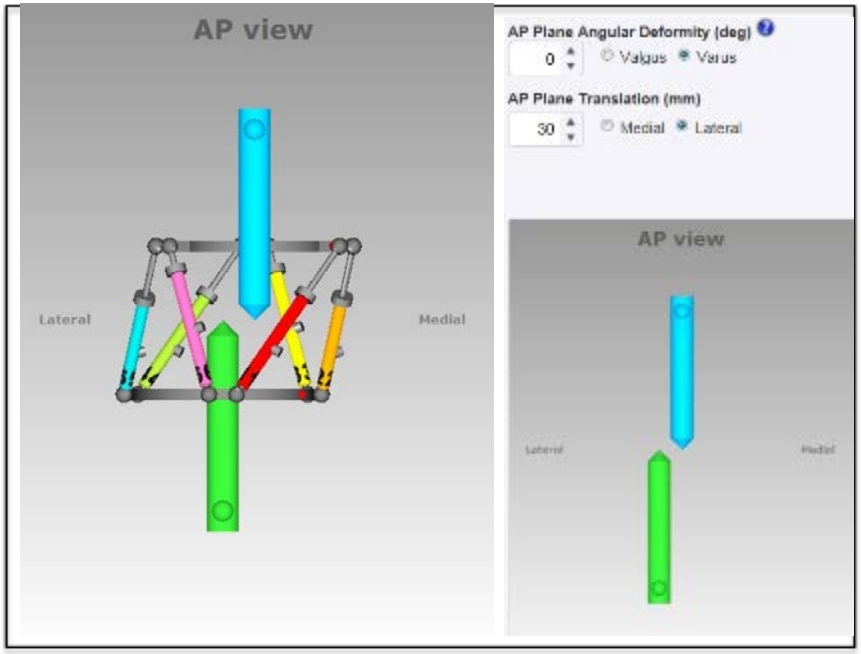

Medial

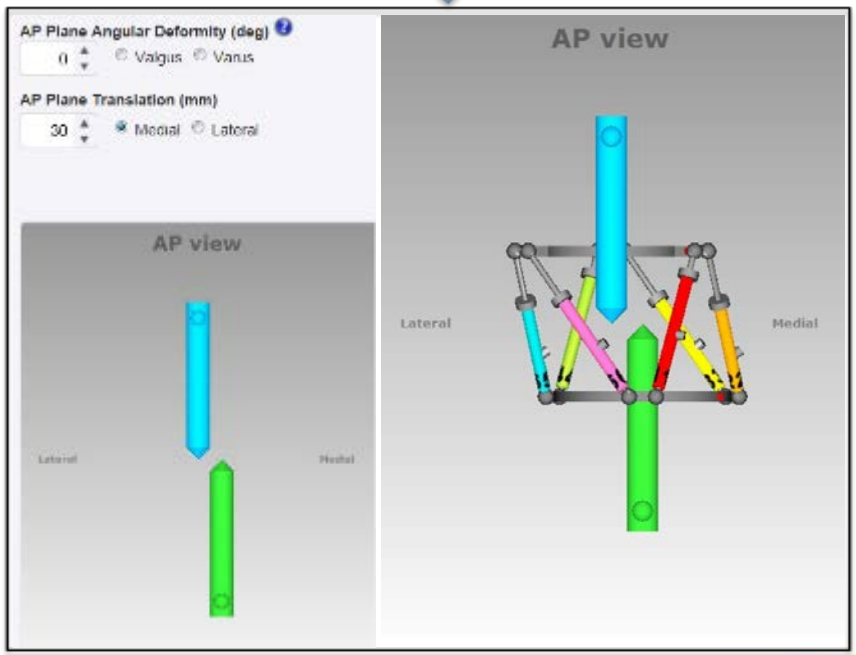

ORTHOFIX

LATERAL VIEW – ANGULATION (5/8 Rings)

RIGHT FOOT

APEX
POSTERIOR/PLANTAR
(Recurvatum)

Xray Medial

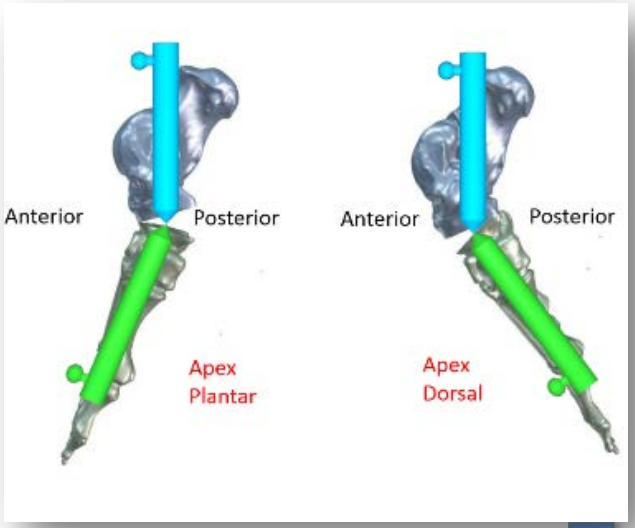

APEX
ANTERIOR/DORSAL
(Procurvatum)

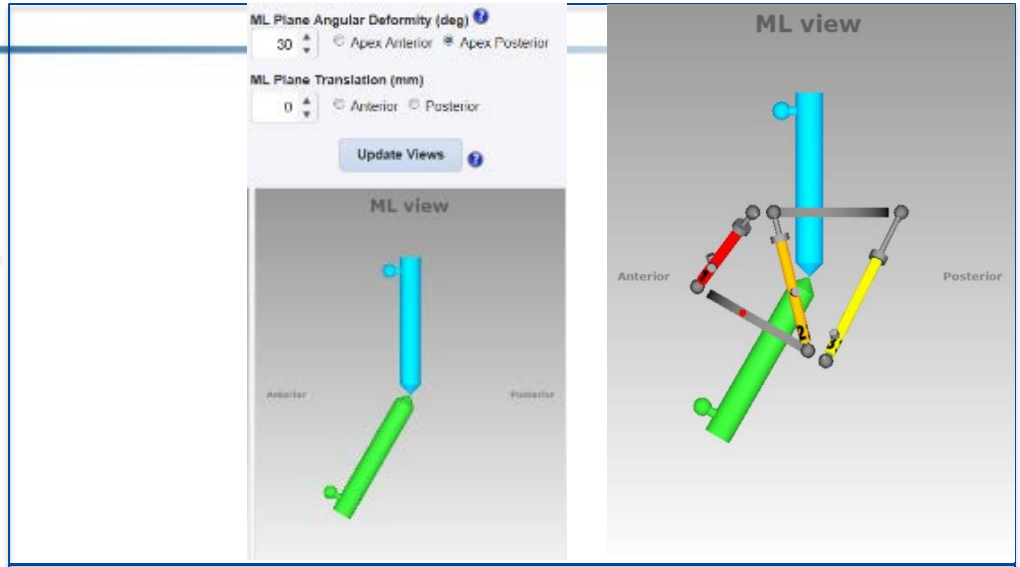

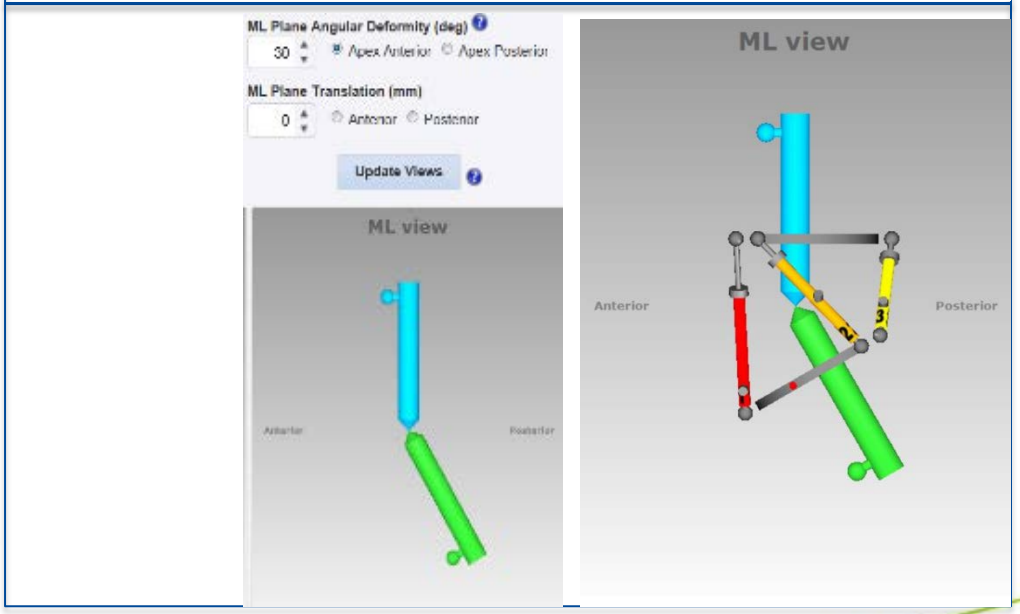

LATERAL VIEW – TRANSLATION (5/8 Rings)

RIGHT FOOT

TRANSLATION PLANTAR
(anterior translation)

Xray Medial

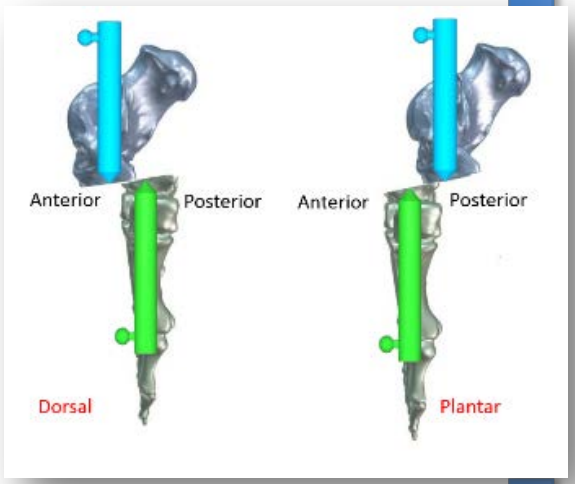

TRANSLATION DORSAL
(posterior translation)

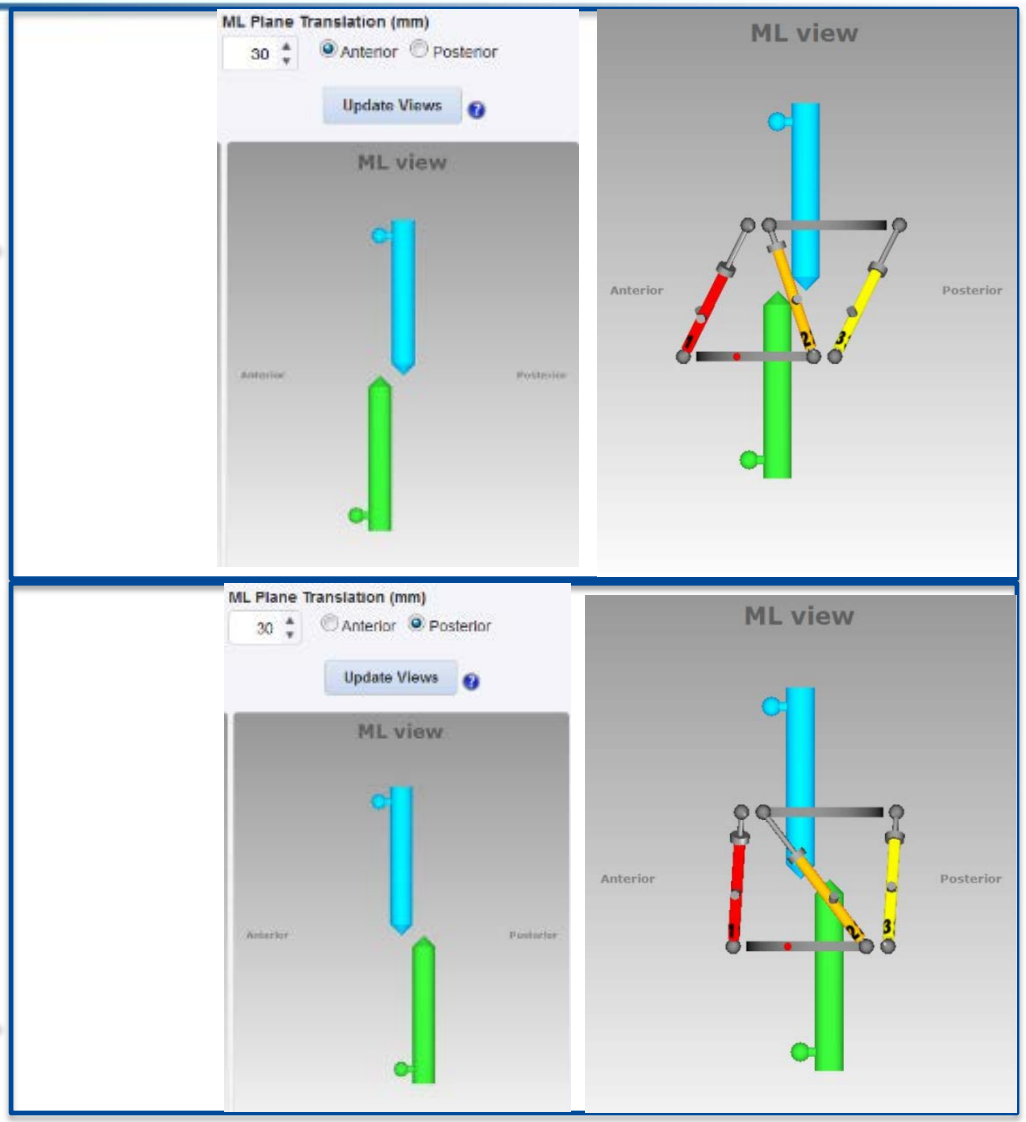

AXIAL VIEW (5/8 rings)

RIGHT FOOT

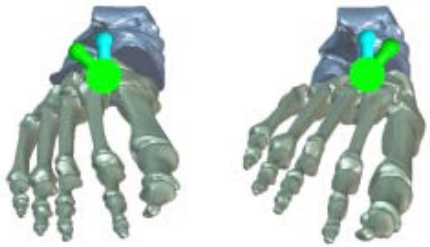

Rotation (deg) 45 External Internal

Axial Translation (mm) 0 Short Long

Bone Length (mm) 0 Short Long

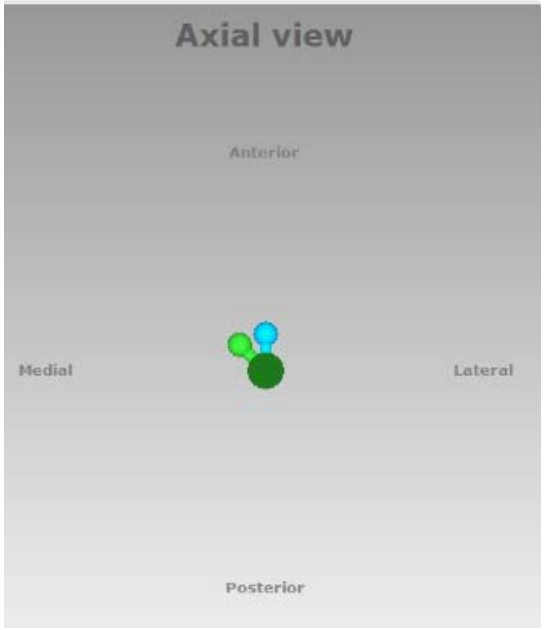

Hindfoot Pronation

INTERNAL ROTATION

Hindfoot Supination

EXTERNAL ROTATION

Rotation (deg) 45 External Internal

Axial Translation (mm) 0 Short Long

Bone Length (mm) 0 Short Long



ORTHOFIX

Full Rings

5/8 Rings

BACK

ORTHOFIX

LEFT FOOT Anatomical – Hindfoot (Reference segment Prox) with Full Rings

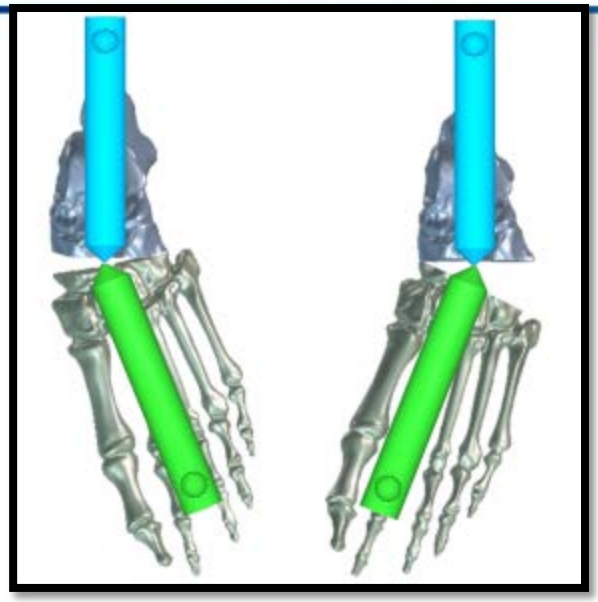

Valgus Varus

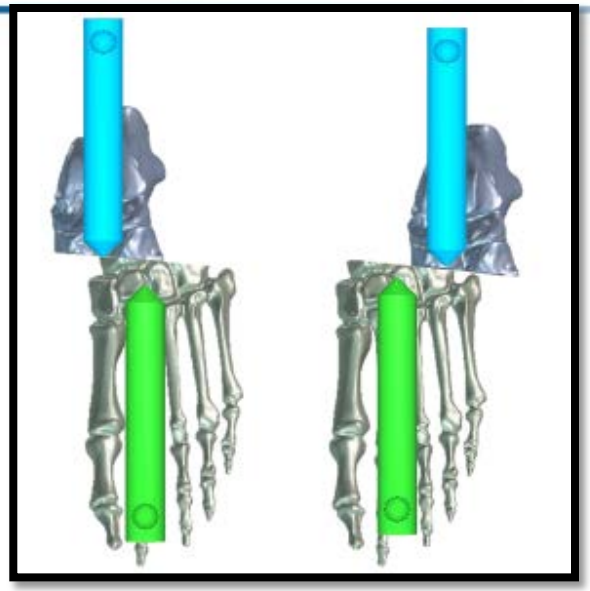

Lateral Medial

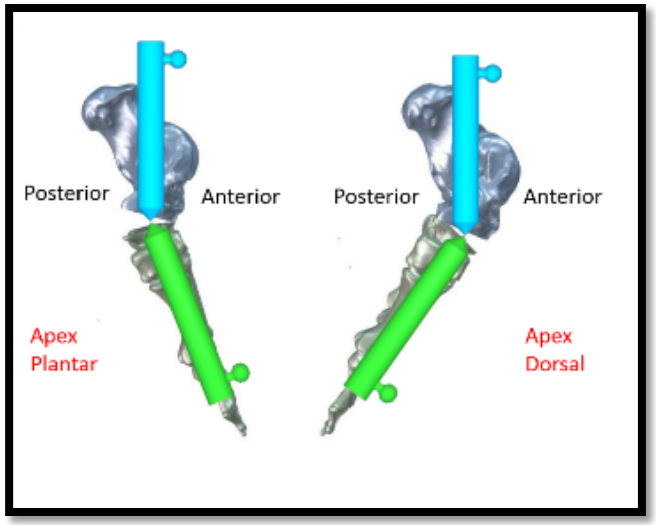

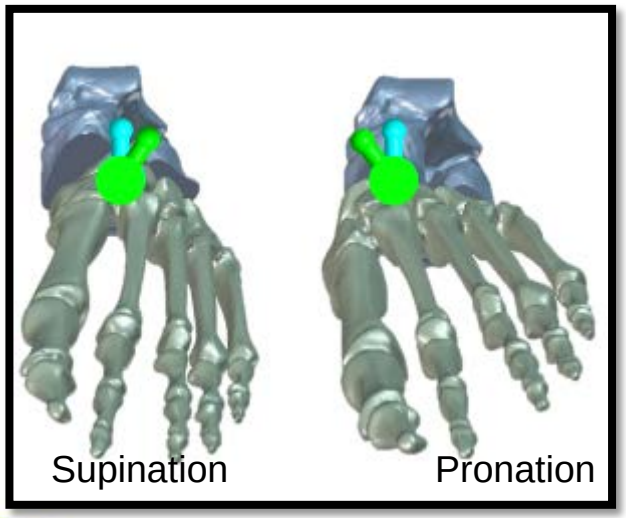

Supination Pronation

Click on Image

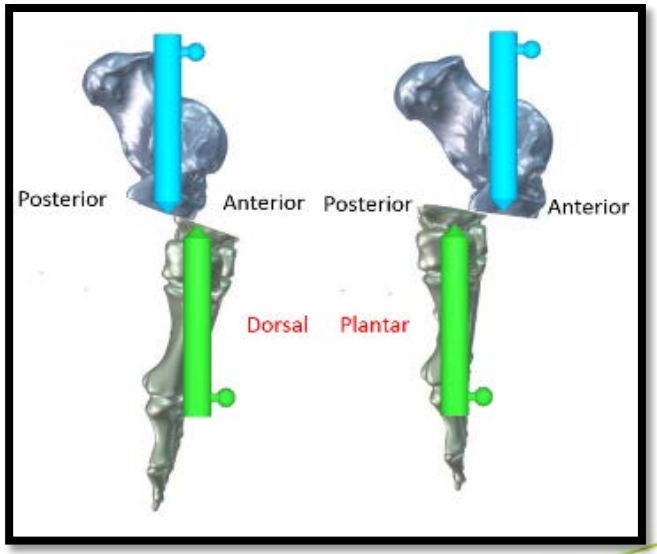

ORTHOFIX

AP View deformity inputs (Full Rings)

LEFT FOOT

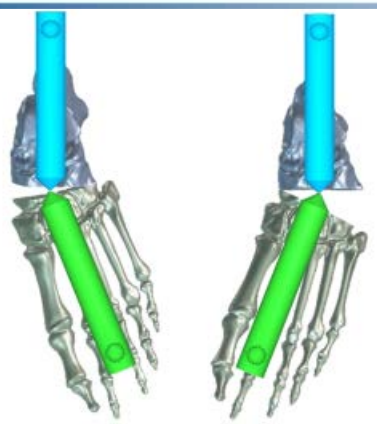

Valgus

Varus

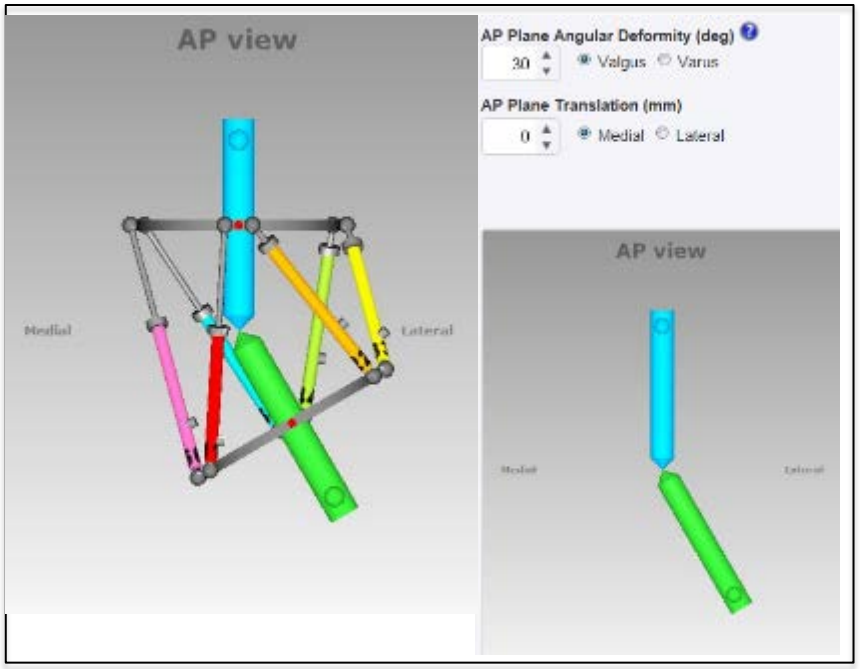

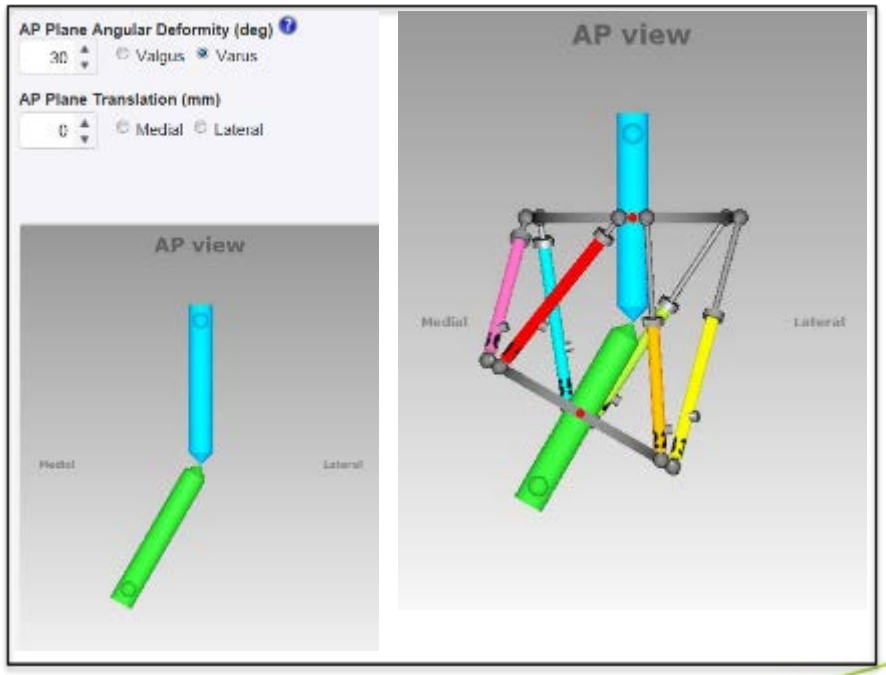

AP View deformity inputs (Full Rings)

LEFT FOOT

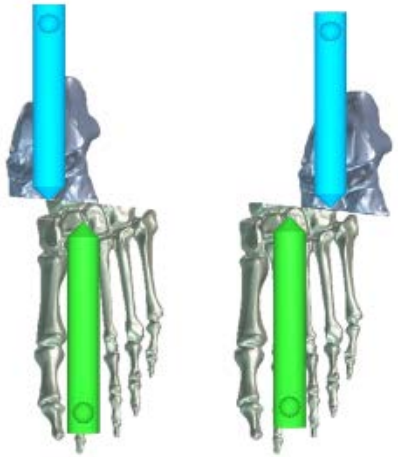

Lateral

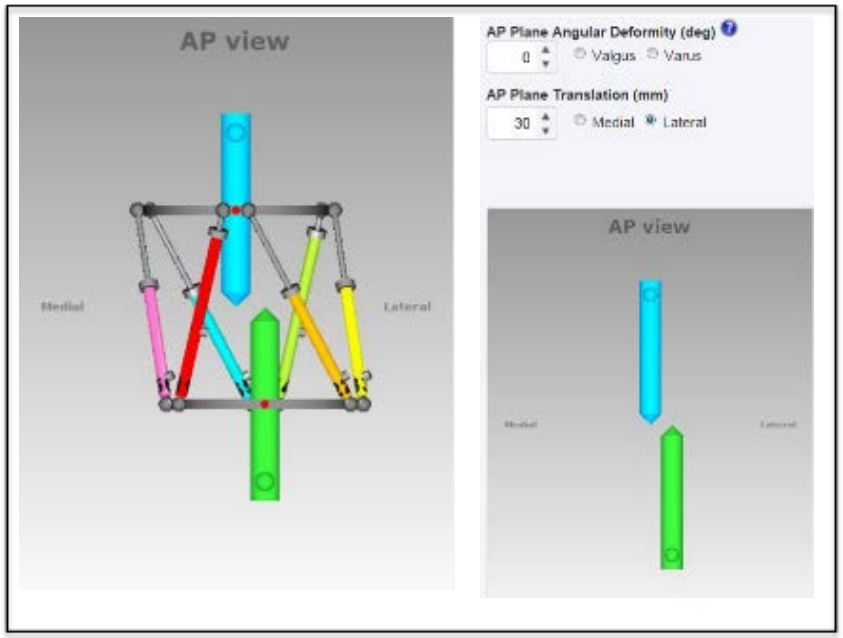

Medial

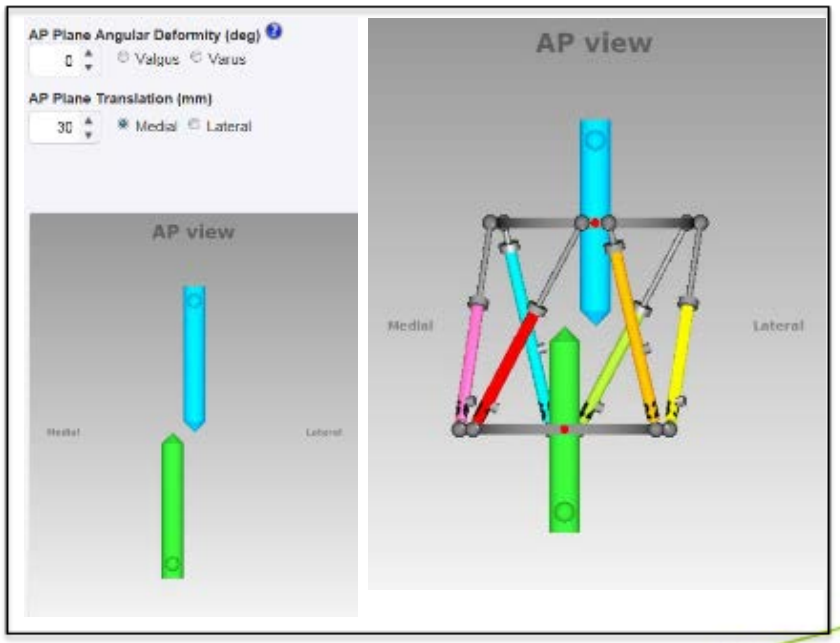

ORTHOFIX

LATERAL VIEW – ANGULATION (Full Rings)

LEFT FOOT

APEX
POSTERIOR/PLANTAR
(Recurvatum)

Xray Medial

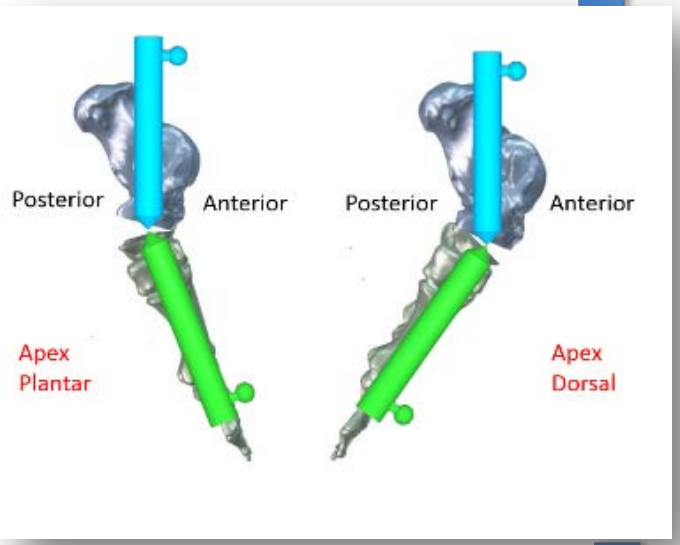

APEX
ANTERIOR/DORSAL
(Procurvatum)

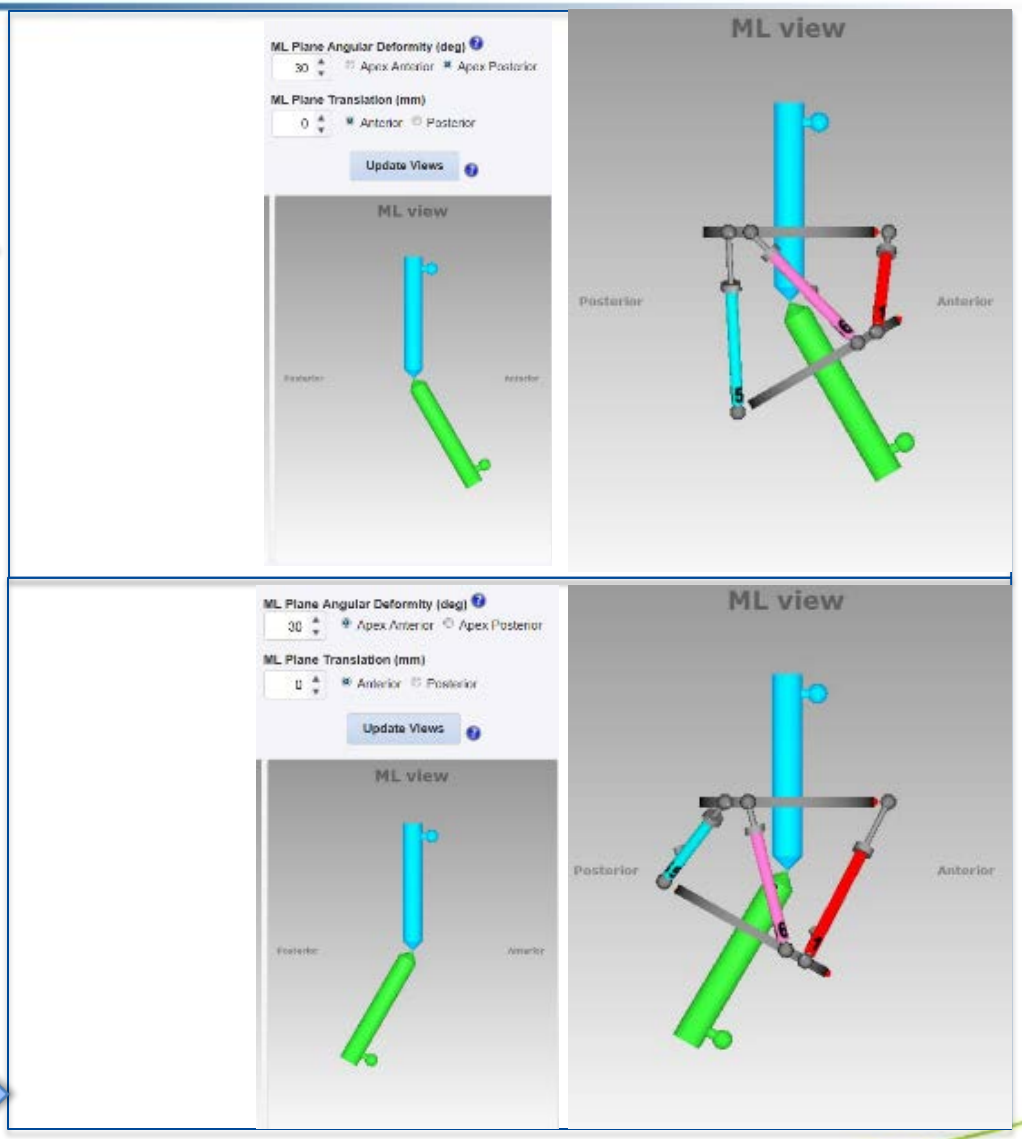

ORTHOFIX

LATERAL VIEW – TRANSLATION (Full Rings)

LEFT FOOT

TRANSLATION PLANTAR
(anterior translation)

Xray Medial

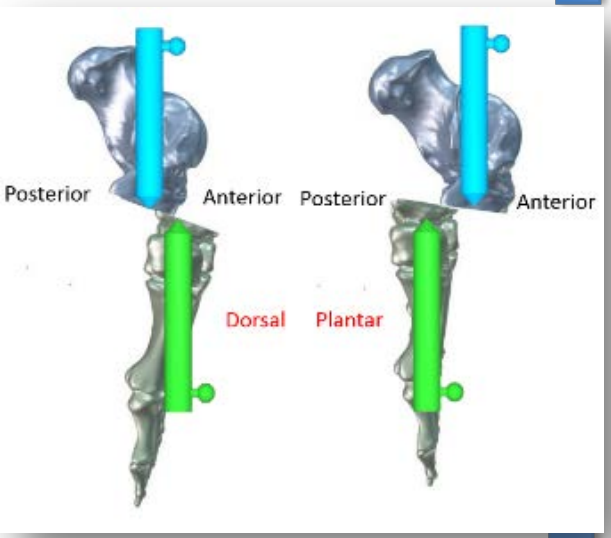

TRANSLATION DORSAL
(posterior translation)

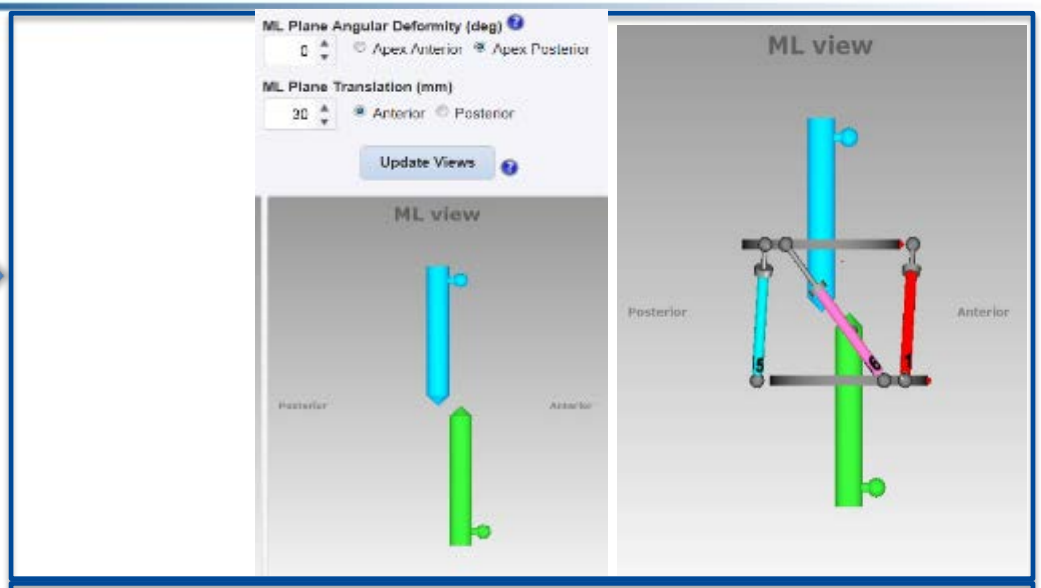

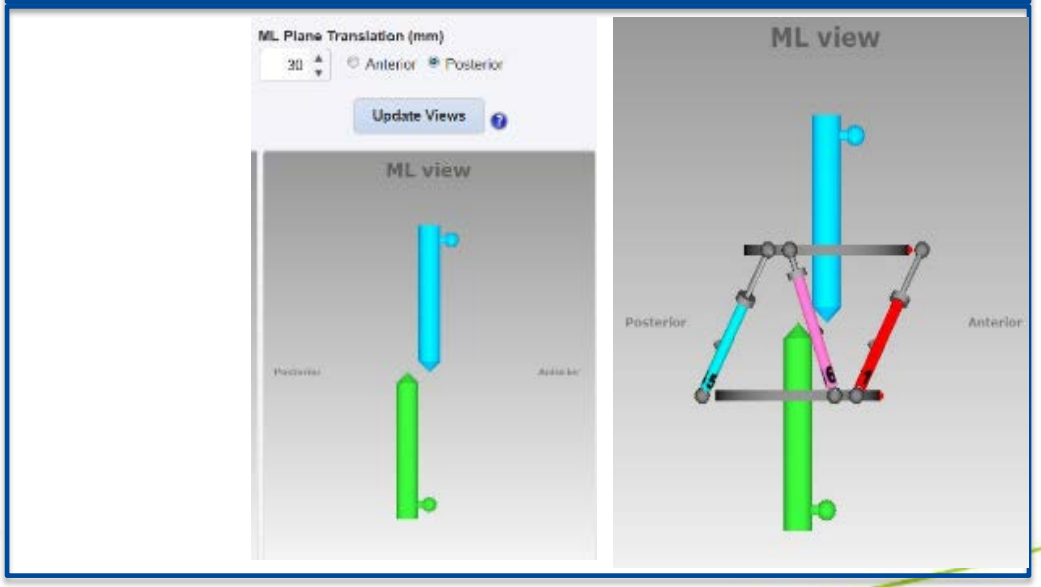

AXIAL VIEW (Full Rings)

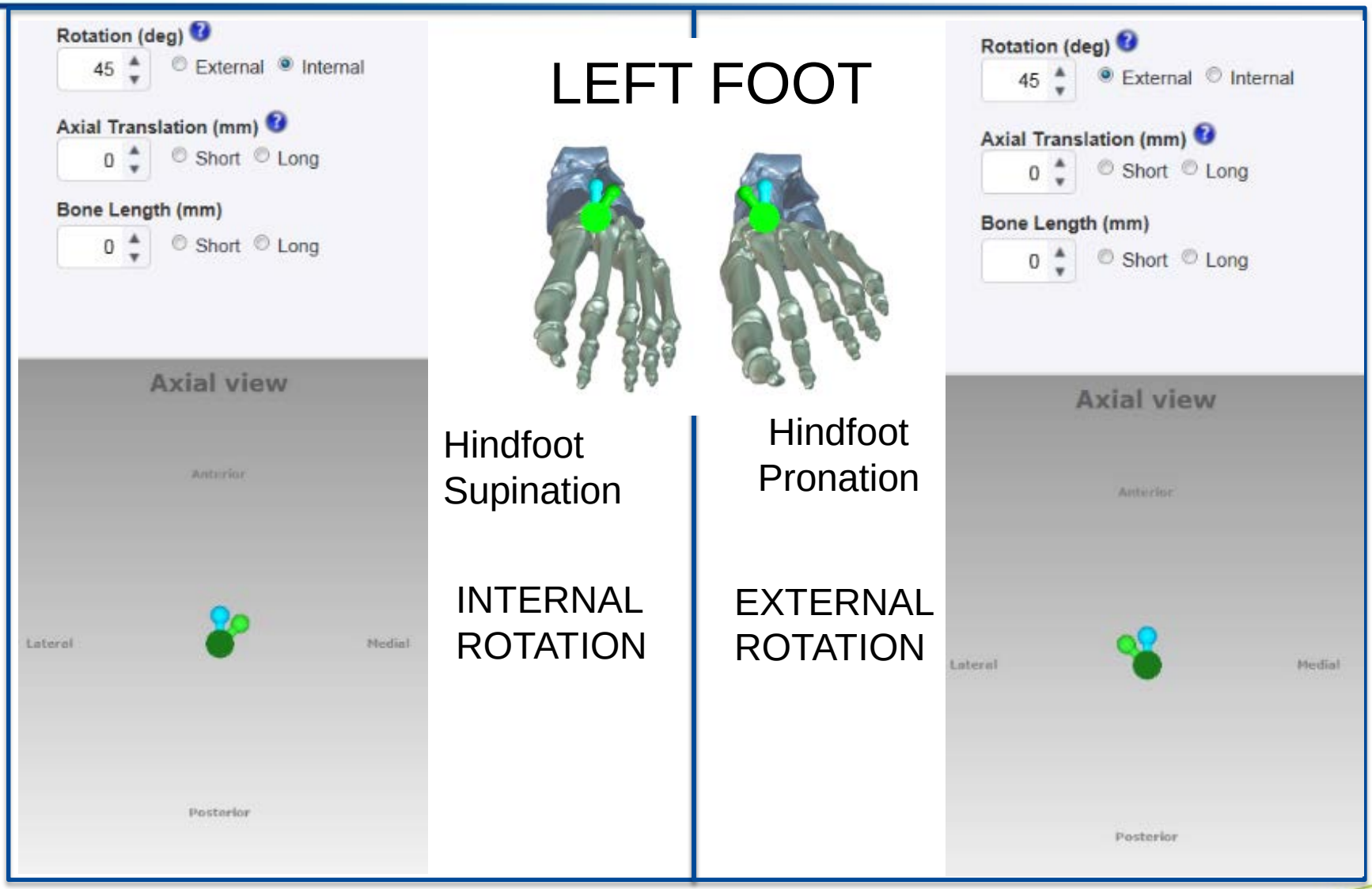

LEFT FOOT Anatomical –Hindfoot (Reference segment Prox) with 5/8 Rings

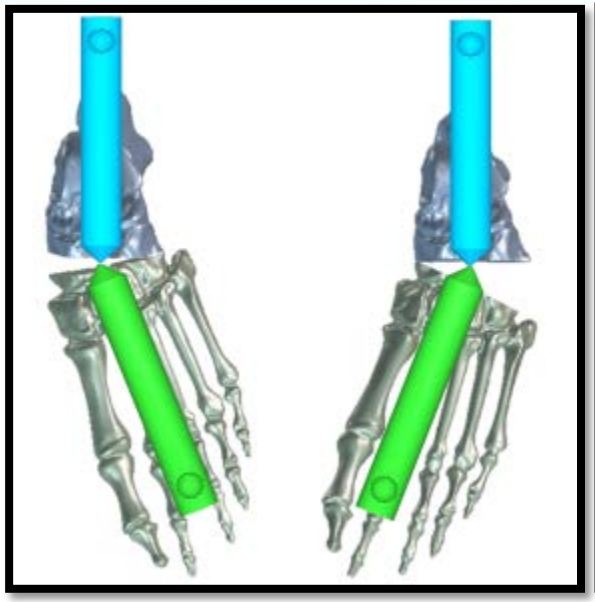

Valgus Varus

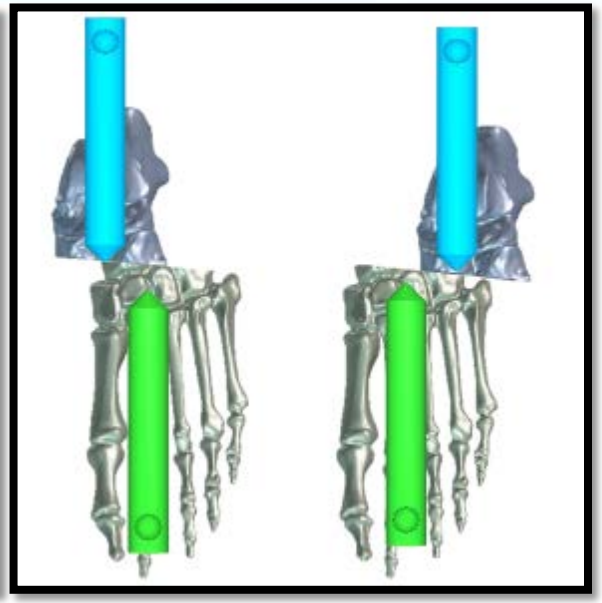

Lateral Medial

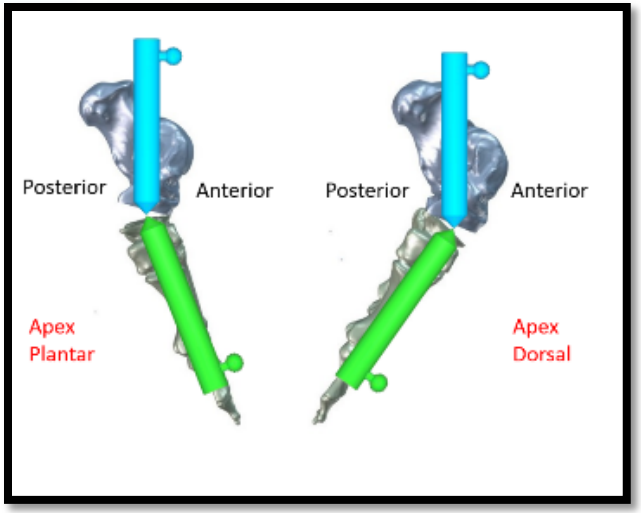

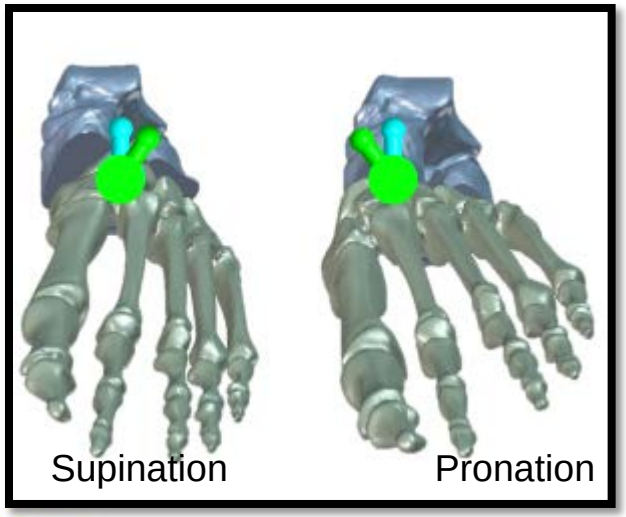

Supination Pronation

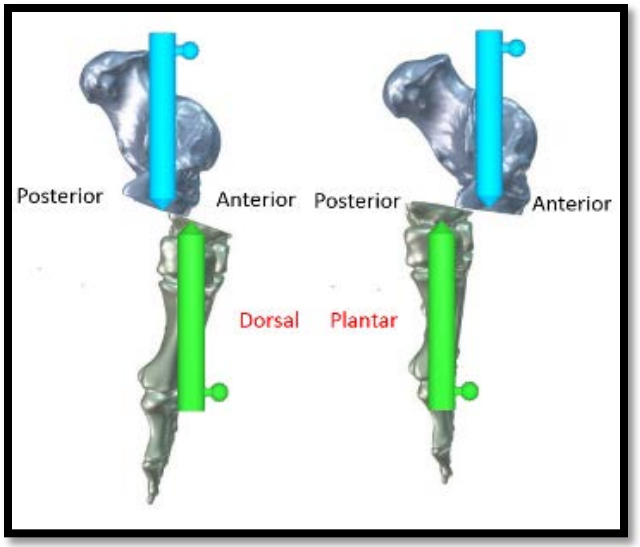

Click on Image

ORTHOFIX

AP View deformity inputs (5/8 Rings)

LEFT FOOT

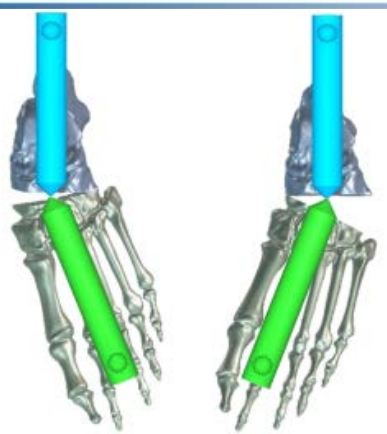

Valgus

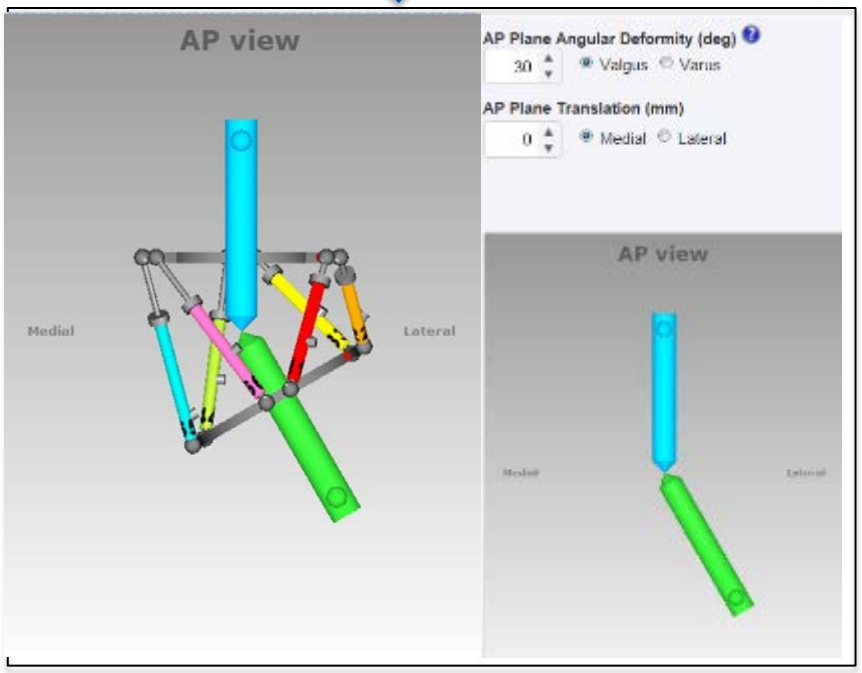

Varus

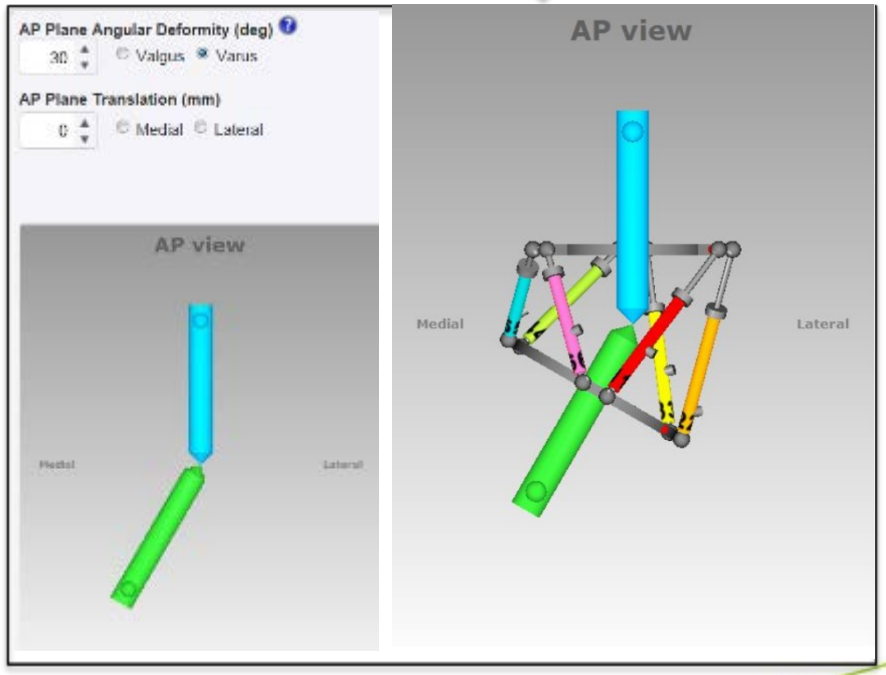

ORTHOFIX

AP View deformity inputs (5/8 Rings)

LEFT FOOT

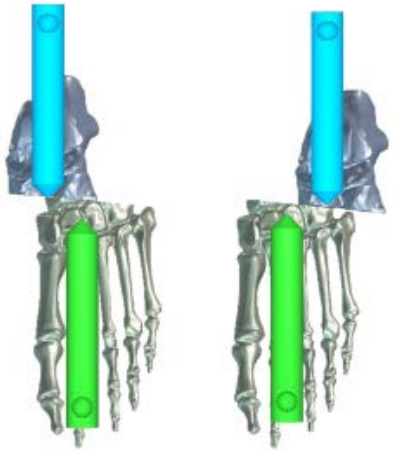

Lateral

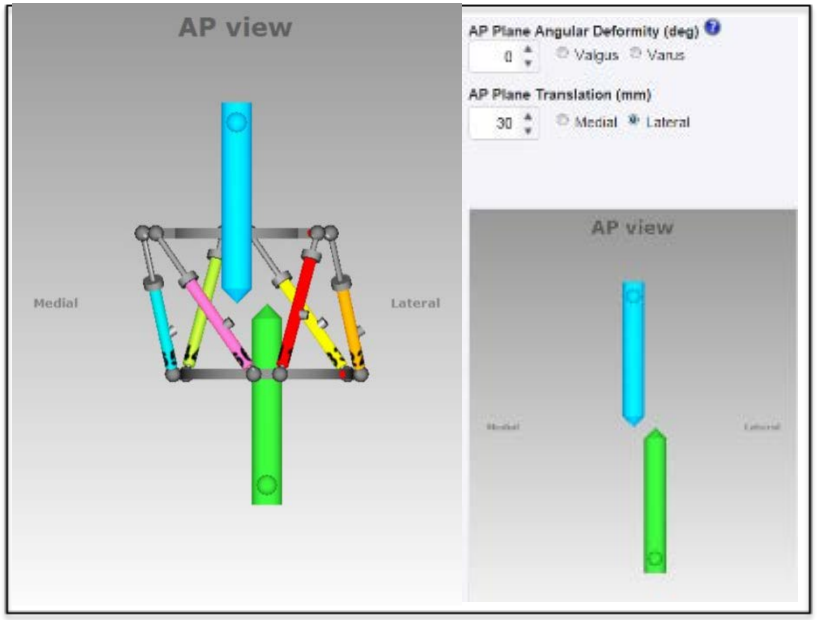

Medial

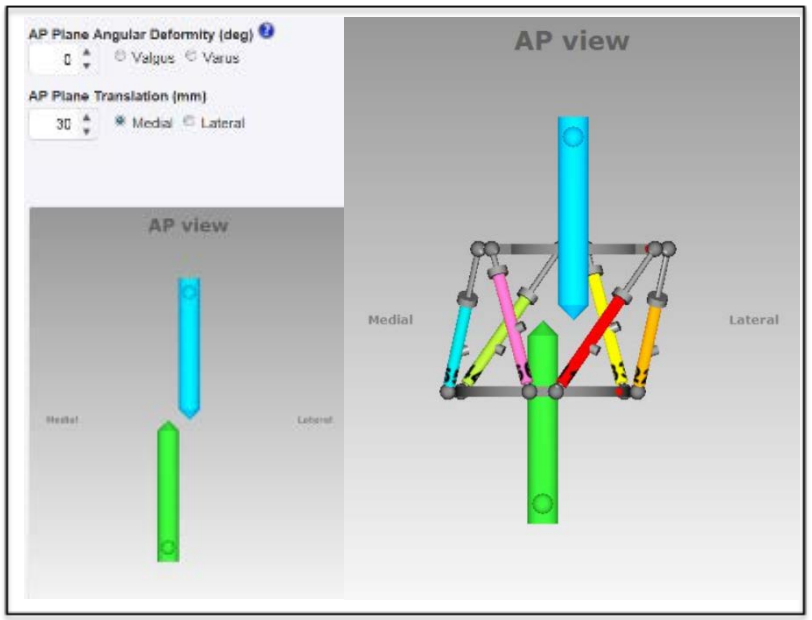

LATERAL VIEW – ANGULATION (5/8 Rings)

LEFT FOOT

APEX
POSTERIOR/PLANTAR
(Recurvatum)

Xray Medial

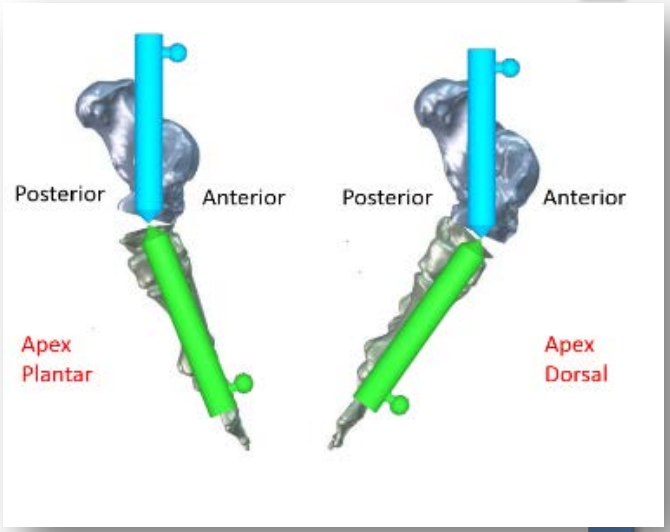

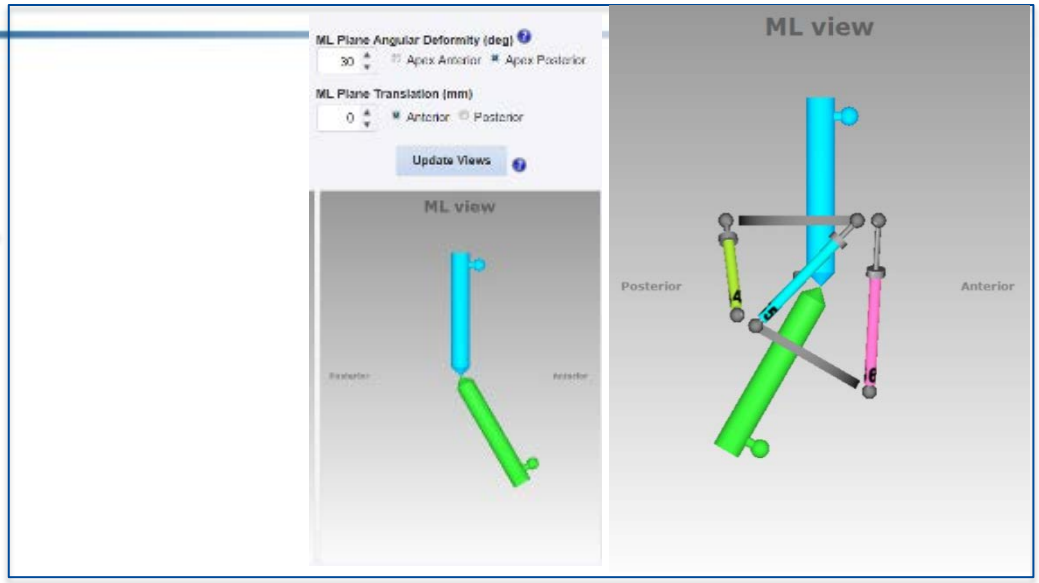

APEX
ANTERIOR/DORSAL
(Procurvatum)

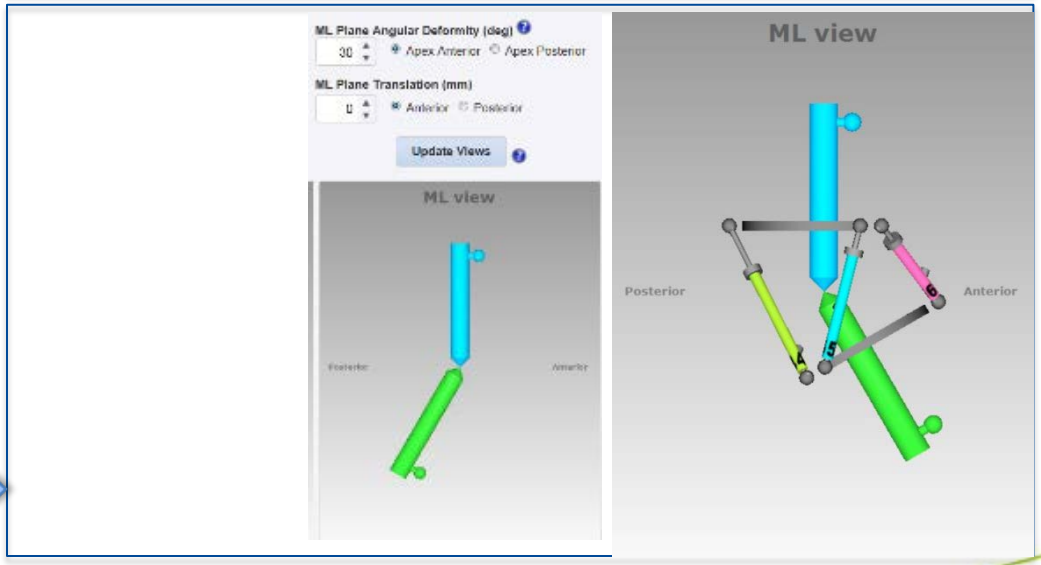

ORTHOFIX

LATERAL VIEW – TRANSLATION (5/8 Rings)

LEFT FOOT

TRANSLATION PLANTAR
(anterior translation)

Xray Medial

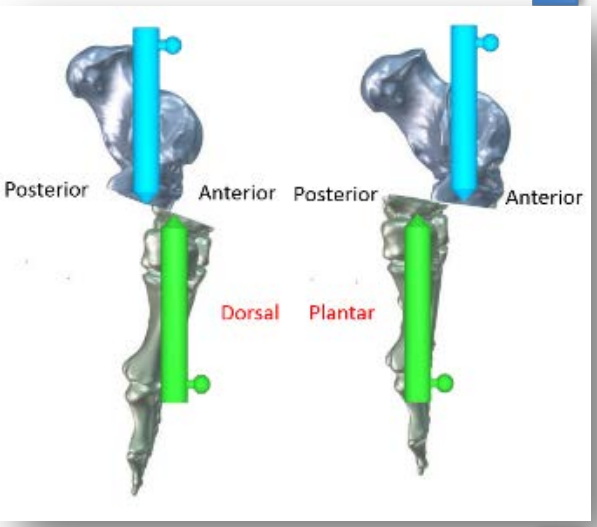

TRANSLATION DORSAL
(posterior translation)

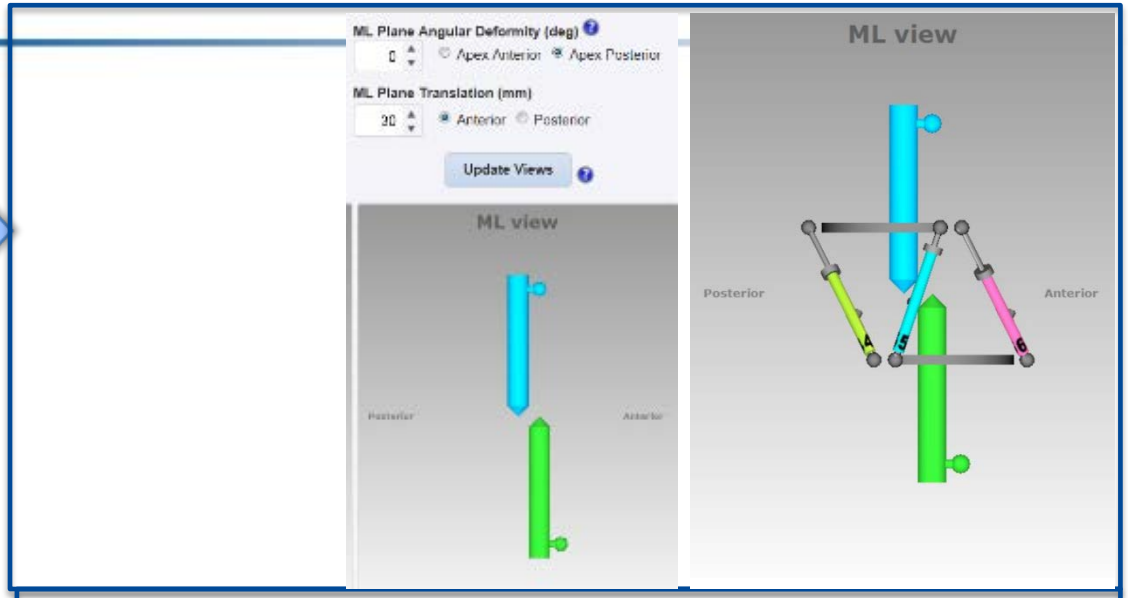

ORTHOFIX

AXIAL VIEW (5/8 Rings)

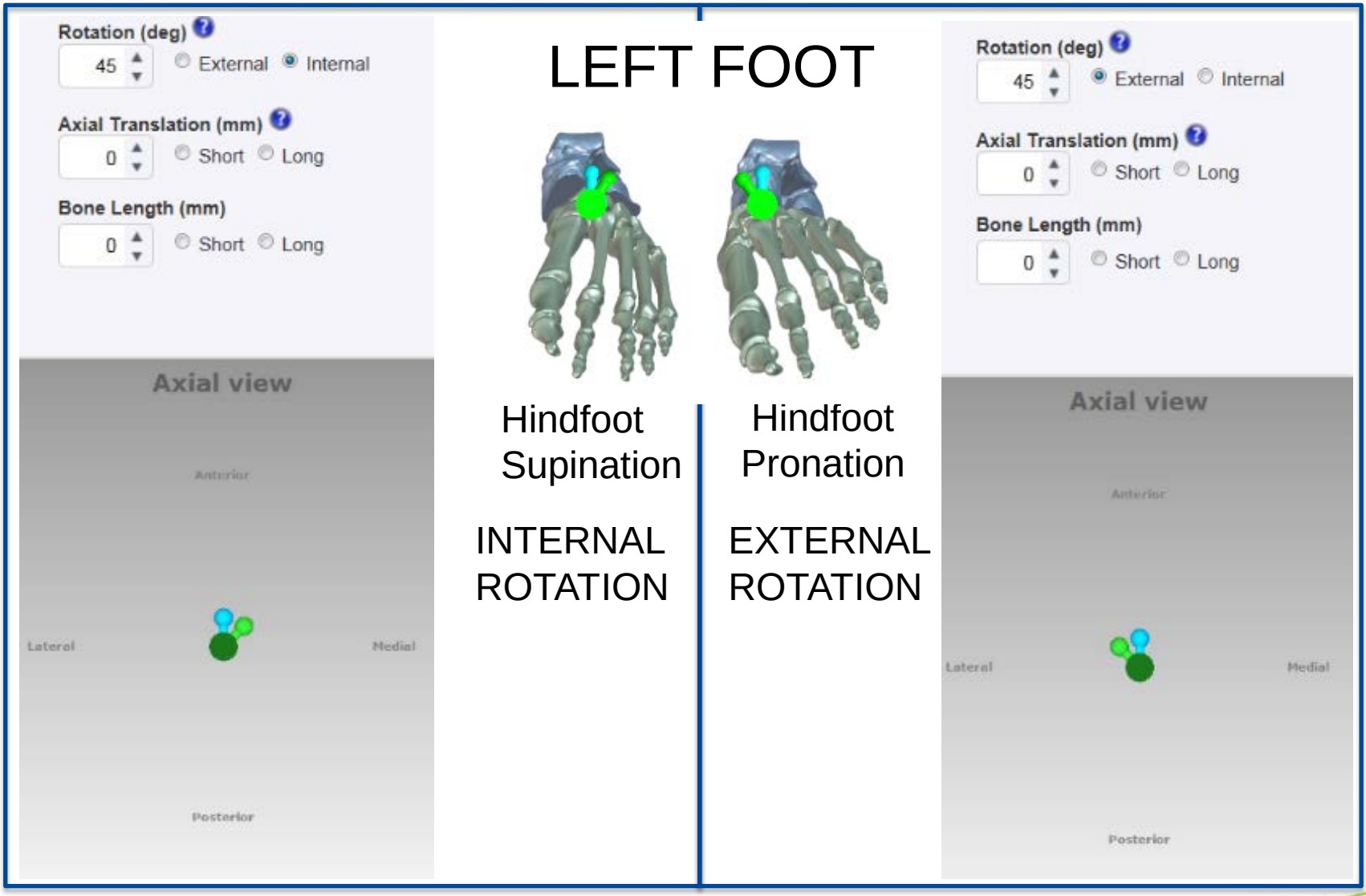

Foot Frame 3D Example
Reference: Distal

ORTHOFIX



Vista 1

Vista 2

Vista 3

Vista 4

Requirements

This installation requires Adobe Acrobat Reader 7.0 or Adobe Acrobat 7.0

You must install one of these products before installation of the plug-in. Adobe products are able on Adobe web site:

www.adobe.com